

1-1-1965

Somatic and autonomic nerves of the lumbar and pelvic regions of the domestic pig.

Yakobo Mabingo Bosa
Iowa State University

Follow this and additional works at: <https://lib.dr.iastate.edu/rtd>

 Part of the [Veterinary Anatomy Commons](#)

Recommended Citation

Bosa, Yakobo Mabingo, "Somatic and autonomic nerves of the lumbar and pelvic regions of the domestic pig." (1965). *Retrospective Theses and Dissertations*. 17917.
<https://lib.dr.iastate.edu/rtd/17917>

This Thesis is brought to you for free and open access by the Iowa State University Capstones, Theses and Dissertations at Iowa State University Digital Repository. It has been accepted for inclusion in Retrospective Theses and Dissertations by an authorized administrator of Iowa State University Digital Repository. For more information, please contact digirep@iastate.edu.

SF 767

S9

B65s

c.2 SOMATIC AND AUTONOMIC NERVES OF THE LUMBAR AND PELVIC
REGIONS OF THE DOMESTIC PIG

by

Yakobo Mabingo Bosa

A Thesis Submitted to the
Graduate Faculty in Partial Fulfillment of
The Requirements for the Degree of
MASTER OF SCIENCE

Major Subject: Veterinary Anatomy

Signatures have been redacted for privacy

Iowa State University
Of Science and Technology
Ames, Iowa

1965

1486598

TABLE OF CONTENTS

	Page
INTRODUCTION	1
REVIEW OF LITERATURE	3
MATERIALS AND METHODS	14
RESULTS	19
DISCUSSION	90
SUMMARY AND CONCLUSIONS	114
BIBLIOGRAPHY	123
ACKNOWLEDGMENTS	130
APPENDIX A	132 a
APPENDIX B	136 a
APPENDIX C	186 a

INTRODUCTION

There appears to be little detailed information available in recent literature about the peripheral nervous system of the pig. For this reason it was felt necessary to investigate this area to supplement the fragmentary and rather inconclusive records encountered in various textbooks. At first the investigation was directed to the lumbosacral plexus, but in the course of this study it was deemed appropriate to include the observations made on the sympathetic trunks related to the lumbosacral spinal nerves, especially their mode of termination in the coccygeal region. It is hoped that the information accumulated on this species can be correlated to practical applications, e.g., applied anatomy in surgery, clinical diagnosis, obstetrical manipulations, and artificial breeding, all of which necessitate a thorough knowledge of the somatic and autonomic nerves of the lumbar and pelvic regions.

With regard to the autonomic system, the emphasis was directed more to the most caudal terminations of the sympathetic trunks, especially as to whether or not they end by means of a ganglion impar, as is the case in man (Gray and Lewis, 1918), or as indicated in the horse (Sisson and Grossman, 1953), and by Botár (1932) who confirms the presence of this ganglion impar in the pig, especially in the female of the species.

Relative to nomenclature, Leutert's 1963 compilation, together with part of the Nomina Anatomica Veterinaria of 1963 have been consulted wherever appropriate, however, the latter does not include the nervous system.

REVIEW OF LITERATURE

As was stated in the introduction, a search of the literature did not reveal much information dealing with the lumbosacral plexus of the domestic pig, with the exception of the dissertation of Reimers (1913). However, utilization was made of information encountered in existing textbooks (Ellenberger and Baum, 1943; Chauveau and Arloing, 1902; Martin, 1923; Montané and Bourdelle, 1920; Patten, 1948; and Sisson and Grossman, 1953). Bearing in mind that the object of this study was to establish a basis for applicability of the findings for day-to-day practice on the pig, much information concerning other animals has been employed in a comparative manner (Sinclair, 1937; Arnold and Kitchell, 1957; Gleland, 1933; Farquharson, 1940; Habel, 1951; Woollard and Norrish, 1933; Heinze, 1964; and Kuntz, 1953).

Part I. Somatic Nerves

Sinclair (1937) pointed out that the distribution of fibers from any given spinal segment presents certain problems whose answers are embryological. As muscles grow they move in a certain direction to their destination and each one carries a nerve fiber with it. Epaxial muscles are innervated by the dorsal or epaxial rami of spinal nerves, which are the primary division of each segment. Limb muscles are innervated by lateral divisions of the lateral or hypaxial rami

after they pass through a plexus for redistribution. Dorsal rami continue without interruption through the region of the limb girdles. No limb muscle receives nerve fibers from only one spinal root and none from more than three, according to Sinclair. During development nerves reach myogenic cells before the latter are grouped into muscles, and the direction of the axis of each muscle is independent of the original course of the nerve fibers, so that each muscle overlaps two or more fields. The fibers then become grouped into nerves to supply separate muscles, and a plexus results. But the distribution of the root fibers retains the original segmental order on the surface of the skin and on the muscles in both limbs and trunk. It is obvious that since the pig has more segments in the thorax and lumbar regions and less in the sacrum than man has, the pelvic limb of the pig has not developed from exactly homologous segments. Despite this, the similarities in detail are striking. With regard to the autonomic nervous system, there is some loss of segmentation pattern, but the order of the fibers to the head and limbs is not changed. The fibers contributing to each limb come from a very broad spinal origin.

Taking the above as a basis of development of the nerves, and considering all other phenomena to be constant, one would expect to find a consistent formation of the lumbosacral plexus. But as all the different aspects of ontogeny are

affected by variations in environment, so one should not expect to find complete similarity in the morphological make-up of all species and individuals.

The lumbosacral plexus of the pig as described by different observers may be, therefore, a reflection of the environmental effect on the specimens, if not a misinterpretation by the various observers.

The nerve roots forming the lumbosacral plexus, as given by Sisson and Grossman (1953), are the last three ventral branches of the lumbar spinal nerves and the first ventral branch of the sacral spinal nerve; Chauveau and Arloing (1902) reported that the nerve roots arise from the last two lumbar and first three sacral spinal nerves, and regarded the trunk that leaves between the last lumbar vertebra and the sacrum as the sacral nerve. Reimers (1913) treated the lumbar and sacral portions independently. He pointed out that the Ramus ventralis of the N. lumbalis VII, sends the main bulk of its fibers to the sacral plexus, and only gives off a relatively slender branch to the nerves of the lumbar plexus. He further pointed out that all of the seven lumbar nerves came into the formation of the lumbar plexus, although all of them do not regularly communicate with each other.

With regard to the number of lumbar spinal nerves, Reimers (1913), Chauveau (1902), Sisson and Grossman (1953), Ellenberger and Baum (1943), and Montané and Bourdelle (1920)

all report that there are usually seven or sometimes six. On the other hand, Uchida (1929), while working on the sympathetic system of the Asian pig, found a constant number of six pairs of lumbar sympathetic ganglia in the trunks, which coincided with the number of the respective vertebrae and spinal nerves. Whereas, Reimers refers to the first of seven pairs of lumbar spinal nerves as the *N. iliohypogastricus accessorius*, comparable to the *N. iliohypogastricus cranialis* in the dog (Miller, Christensen and Evans, 1964) or of the cat and rabbit (Langley and Anderson, 1896); Ellenberger and Baum (1943) refer to this nerve as the *N. iliohypogastricus cranialis*. But when there are only six pairs of lumbar nerves, the reduction leads to having a *N. thoracis accessorius*, according to Reimers (1913). Work by Kitchell, Campbell, Quilliam and Larson (1955) elucidating sexual behavior in other species indicated certain lines of study that could also be carried out on the pig. This work also revealed the existence of controversy in the nomenclature of certain nerves, for example, of the two terminal branches of the pudendal nerve (*N. pudendus*), in the female the term for one, the *N. clitoridis* is commonly accepted, but the other, which proceeds to the mammary glands, is given various names, *N. mammarius* (Habel, 1951), *N. perinealis* (St. Clair, 1940), or *N. perinealis superficialis*, (Larson, 1953).

Schneider and Zintzsch (1962) have indicated landmarks

for nerve blocks on the extremities of the limbs in the pig.

According to Reimers (1913) there is no communication between the ventral branches of the first two lumbar spinal nerves. The L₃ spinal nerve is the N. ilioinguinalis, which sometimes receives a reinforcing branch from the L₂ spinal nerve. The union of branches from the L₃ and L₄ spinal nerves gives origin to an independent nerve, the N. spermaticus externus (N. genitalis). The latter nerve arises from the L₄ spinal nerve according to Reimers (1913). He states also that the N. genitalis (spermaticus ext.) seldom gives off a twig to the N. cutaneus femoris lateralis. The N. cutaneus femoris lateralis arises from the L₅ spinal nerve, and, in about one third of the cases it receives a contributory branch in its initial course from the L₆ spinal nerve. The N. femoralis is said to arise from the L₆ spinal nerve in common with the N. obturatorius. He notes an inconstant, reinforcing, slender branch from the L₇ spinal nerve in the N. obturatorius, and also apparently continuing fibers from the L₅ spinal nerve to the N. obturatorius.

In the sacral region four pairs of sacral spinal nerves are constantly noted by Reimers (1913). He describes the last lumbar spinal nerve with the sacrals which form a large integral part of the sacral plexus. The L₇ spinal nerve receives a reinforcement from the L₆ spinal nerve, mostly via the N. obturatorius. The N. cutaneus femoris caudalis is

noted to come from the S_2 spinal nerve. The Nn. pudendus and haemorrhoidalis medius (N. rectalis medius) arise from the S_3 spinal nerve. In most cases, the origin of the N. gluteus caudalis is before, and in a few cases after, the N. cutaneus femoris caudalis arises from the ischiatic plexus. Reimers points out that, in one case out of ten, the N. cutaneus femoris caudalis gave off a small loop to the N. pudendus. The latter nerve is said to come from the S_3 spinal nerve, reinforced by the S_2 spinal nerve. The N. pudendus was also shown by him to give off three cutaneous branches designated as the proximal, distal and middle cutaneous nerves. One branch, corresponding to the proximal nerve referred to above, arose directly from the S_3 spinal nerve at the intervertebral foramen.

While there are two spermatic trunks in cattle, according to Reimers (1913), only one trunk, which arises from the L_3 and L_4 , or L_2 and L_3 , (depending upon the presence of seven or six lumbar spinal nerves), is found in the pig. In addition, he states that in horses, cattle and pigs with six lumbar vertebrae the N. cutaneus femoris lateralis arises from the L_4 and L_3 spinal nerves, while in pigs with seven lumbar vertebrae it arises from the L_4 and L_5 spinal nerves.

He further points out the important differences existing between the lumbar plexus of man and that of domestic animals, and moreover, the differences between the plexuses of the horses, cattle and pigs.

Part II. Autonomic Nerves

The investigations that have been carried out in connection with the somatic nerves of the lumbosacral plexus, led to the necessity of correlating the respective portion of the autonomic nerves by gross observations, especially the termination of the sympathetic trunks in the sacro-coccygeal region. So far the most comprehensive information relating to the sympathetic system in the pig is found in the dissertation work of Uchida (1929), but it deals with the portion cranial to the sacral region. Botár (1932) worked in the same area as the present author. The autonomic nerves of the dog have been more fully investigated (Mehler, 1951 and 1952; Mizeres, 1955; Cloninger and Green, 1955). The neurological studies by Kitchell, Campbell, Quilliam and Larson (1955) on domestic animals, although not including the pig, should not be ignored. Langley and Anderson's (1896) work on the cat and rabbit throws light and caution as regards generalizations which have been relied upon in many instances not only in veterinary work but also in human medical experiments. Larson's (1953) work and that of Dziuk et al. (1954b) further indicate the need for a thorough understanding of the sympathetic system in each and every species of our domestic animals, especially the pig. As indicated by Sisson and Grossman (1953) the autonomic nervous system in the pig has been neglected. It should be pointed out that only some

aspects of the sympathetic nerves have been taken into account and much more needs to be investigated. Just as the present work was still going on, Zintzsch (1964) has published much the same work done on the sheep in the same area as is being pursued in the pig.

Uchida (1929) and Botár (1932) have done commendable work on the sympathetic nerves of the domestic pig, although the work of the former does not extend beyond the lumbar region. Botár's work seems to indicate two patterns in the sacrococcygeal region which are influenced by sex difference. Others (Mizeres, 1955; Langley and Anderson, 1895; Trumble, 1934; Oppenheimer, 1938; Dyce, 1958; and Zintzsch, 1964) have worked on the autonomic nervous system of other animals and man, and have helped to open the door for further work of a similar nature on the pig.

In addition, there are some practical applications which need to be considered. Such work as the collection of semen from bulls, goats, rams and boars, (Dziuk, Graham, Donker, Marion and Peterson, 1954a) by the use of electrical stimulation, necessitates knowledge of the nerves which come into play to produce the desired effect.

Botár's work (1932) also includes the sympathetic nerves of the other domestic mammals. Dyce's work (1958) was on the sympathetic system of the horse. Woollard and Norrish (1933) give a simplified view of the sympathetic nervous system for surgical purposes in their summary:

From a surgical point of view the sympathetic innervation of any particular region can be determined by the method of macroscopic dissection. Innervation fibers that cannot be determined by this method are not of surgical moment.

The same authors (1933) indicated the complexity of the nervous supply to the viscera, there being no constant pattern in this source, reporting that they may be received from the adjacent plexus, from branches proceeding from ganglia, or in the fibers which accompany the blood vessels. Representation may either be oversimplified, if a great deal of cleaning of the area is done, or may be overwhelming when the plexus is photographed. Another approach used by many investigators to elucidate the situation, is to perform a sympathectomy, which alleviates a functional discomfort stemming from the sympathetic nervous system.

Kuntz (1956), speaking about the intermesenteric nerves in man, points out that the middle nerves lead into the inferior mesenteric plexus, and the lateral ones extend into the hypogastric plexus. He reports on the presence of special ganglia in the greater splanchnic and lesser splanchnic nerves in man. He also points out the occurrence of a posterior renal ganglion and aortico-renal ganglion, which are also reported in the dog (Miller, Christensen and Evans, 1964). The unmyelinated fibers -- chiefly postganglionic, but some undoubtedly afferent -- increase, and the myelinated ones decrease in number from the proximal toward the distal ends

of the nerves. This change is correlated with the occurrence of ganglia in the nerves.

The lumbar splanchnic nerves, which number four in the cat (Kuntz, 1956), either terminate in the renal plexus or caudal mesenteric ganglion, and contribute rami to the intermesenteric ganglia, and some, also, to the hypogastric plexus. Direct rami go to the aorta. Macroscopic ganglia are said to be observed rarely in the lumbar splanchnics in the cat, except near the caudal mesenteric ganglia. Although microscopic ganglia are observed they are not present in all nerves in a single animal. Ganglion cells also occur in sympathetic rami that extend toward the aorta along the segmental vessels.

Langley and Anderson (1895), after sectioning the dorsal roots of the sacral spinal nerves, found that there were degenerations of nerves to the bladder and rectum, fewer to the urethra and vulva, but none to the uterus and vagina in the cat and rabbit. Therefore, they concluded that the sacral nerves do not send sensory fibers to the internal genital organs in these species.

The pelvic nerve (N. erigentes) in the cat, is composed of about one-third afferent fibers. In addition, it contains a few fibers that do not degenerate after sectioning the sacral nerves. Branches of the pelvic plexus to the rectum and their modulated fibers are almost entirely sacral afferent fibers. The efferent rectal fibers are connected

with nerve cells in the first group of ganglia occurring on the course of the pelvic nerve. The hypogastric nerve gives a considerable number of medullated fibers to the bladder and uterus, less to the vagina, and a few, or none, to the urethra, in the cat.

MATERIALS AND METHODS

Part I. Somatic Nerves

Fifteen pigs, eight females and seven males (four castrated), of various breeds (six Yorkshire, three Poland-China, two Landrace and four Yorkshire-Landrace), ranging in age from 3 months to 6-1/2 years, were used.

Most of the specimens were prepared and embalmed in the manner commonly followed in the department, while a few of the animals were dissected in the fresh state. The animals to be embalmed were first anesthetized with pentobarbital sodium, bled by carotid cannulation and then infused with an embalming fluid consisting of: 60 percent Isopropyl alcohol, 4 percent Formaldehyde, 6 percent Liquid Phenol, 2-1/2 percent Corn syrup (50 percent H₂O) and 27-1/2 percent Water. Following embalming and throughout the investigation the specimens were kept in cold storage between dissections.

The specimens not embalmed were from animals which had been electrocuted and then bled immediately. These were gerontological specimens, but they provided the essential areas for study in the lumbosacral region. These specimens were kept in cold storage also whenever not being worked upon, but, of course, after some time it was necessary to immerse them in a solution of 10 percent formaldehyde.

Two methods of approach were followed. The first, which was always necessary in the sacral portion, was to

dissect from outside to inside. In this method the skin was incised along the mid-dorsal line and reflected ventrally towards the flank. The lumbar and gluteal muscles were incised one-by-one, reflected, and finally removed as the nerves were dissected to their intervertebral exits. In the first three specimens a laminectomy was performed with concomitant removal of the ossa ilia. However, it was found that the nerves were easily broken before the dissections, so the removal of the ossa ilia was abandoned.

In most cases the second method was pursued, especially for the nerves in the lumbar region. This method consisted of making a longitudinal incision along the mid-ventral line, allowing the removal of the abdominal viscera up to the pelvic inlet, but temporarily leaving the internal genital organs, bladder and rectum in place. As the dissection progressed these organs were removed as necessary. The sub-lumbar muscles (*Mm. psoas major and minor*) were removed piecemeal, as were the *Mm. iliacus, obturatorius internus, sacrococcygea ventrales, and coccygeus*, so as to expose the point of emergence of the spinal nerves. The aorta was temporarily left in place in specimens in which the sympathetic nerves were closely observed, otherwise it was removed, together with its terminal branches, after noting the relationship these had with the various spinal nerves.

Photographs were taken and drawings made of the exposed

structures. These will be found appended to this thesis.

All work was carried out macroscopically, except in one case in which microscopic means were resorted to in order to identify what appeared to be an unusual nerve connection to the N. retractor penis.

In order to make the nerves stand out clearly for photographic procedures, the spinal nerves were painted with yellow latex. Since India ink tends to spread to surrounding tissues, black casein paint¹ was employed for the sympathetic nerves.

The area studied and dissected extended from the last rib caudad, though in one case the dissection was extended to include the last four ribs so as to identify and study the sympathetic trunks.

In one of the specimens (no. 5) the vertebral canal was opened in order to observe the extent of the spinal segments of the cord as indicated by the spinal nerve emergence from the surface of the spinal cord, with and without its meninges. For this the Stryker saw was used to remove the dorsal arches of the vertebrae, and thus expose the spinal cord and its membranes (Plate 3).

Observations were also extended to the dorsal branches of the spinal nerves in the lumbosacral region (Specimen no. 7) (Figure 6; Plates 6 and 7).

¹Casein colors prepared by R. Shines of 433 W. Coethe Street, Chicago, Illinois.

Part II. Autonomic Nerves

Five of the specimens which were being used for the study of the lumbosacral plexus have been used also to observe the autonomic nerves in the areas indicated in the introduction. Two of these however were not as carefully treated for this purpose, although some information was collected from them in the light of correlating findings. The remaining three have been so treated as to obtain a clearer picture of the arrangement of the sympathetic trunks. Two of the specimens were females and the rest males, of which one was castrated.

The abdominal viscera, except the kidneys and the terminal portion of the colon and pelvic organs, were removed through a sagittal opening on the ventral aspect of the abdominal wall. A bit of the mesentery was left on the dorsal wall of the abdominal cavity together with the aorta. More working space was obtained by removal of the portion in front of the last four ribs.

Dissection proceeded by gentle removal of the parietal layer of the peritoneum along the lateral borders of the M. psoas major, reflecting it medially. While the various nerves were being located, the M. psoas major and M. psoas minor were removed piecemeal, following the Rami communicantes toward the spinal nerve at their site of emergence. Then the parts in proximity to the aorta were traced toward

the caudal end into the pelvic cavity.

Two more female pig specimens were investigated, making a total of seven specimens on which the autonomic system was examined. One of the specimens after yielding such unexpected results led to the investigation of yet another one of the same sex. The only unfortunate thing about one of these specimens is that it consisted of only a small part of the lumbar region although the sacral and coccygeal regions were almost completely intact with regard to the *Trunci sympathici*. This specimen had three lumbar vertebrae left and there were still two pairs of lumbar sympathetic ganglia, although one of the ganglia was represented by an extraordinarily placed ganglion on the right side, so that only one ganglion was present on the left side. The Aorta abdominalis and the Vena cava caudalis had already been removed and therefore all of the lumbar splanchnic nerves had been destroyed. The rectum and genitalia and also the pelvic plexus had been removed as far as the caudal third of the pelvic cavity. However, some interesting information was provided by this specimen which was dissected fresh. It was the fourteenth in the series of specimens dissected for the lumbosacral plexus.

The other specimen was a whole pig treated in the usual way of embalming and was prepared for dissection as described above. It was the seventh specimen examined for the *Tr. sympathici*, the fifteenth in the series of dissections for the lumbosacral plexus.

RESULTS

Part I. Somatic Nerves in the Lumbosacral Region

The Lumbosacral spinal nerves

In all, except two, of the specimens examined there were six pairs of lumbar spinal nerves, and four pairs of sacral spinal nerves. Of the two exceptions, one had five pairs of lumbar, and four pairs of sacral spinal nerves; the other had four pairs of sacral spinal nerves, but the lumbar nerves could not be determined, as only the pelvic part had been saved for determining the terminations of the sympathetic trunks in the sacral and coccygeal regions.

In the following findings, the last pair of thoracic spinal nerves were included and have been described first as the cranial landmark for the area examined.

The last thoracic spinal nerve

The ventral branch of the last thoracic spinal nerve of each side leaves the vertebral canal at the caudal end of the last thoracic vertebra. It is so placed that it appears to be a considerable distance from the last rib, especially at the nerve's emergence from the intervertebral foramen. It runs almost parallel to the last rib, and at the lateral border of the *M. quadratus lumborum*, it enters the vertebral border of the *M. transversus abdominis* in company with the

cranial-most branch of the A. phrenico-abdominalis. The nerve divides into two branches in the upper third of its course. One of these branches passes outwards and innervates the M. obliquus externus abdominis, M. cutaneus trunci, and the skin. The second branch descends in a caudoventral direction in the substance of the M. transversus abdominis, gives a twig to it and continues ventrocaudally and finally enters the lateral border of the M. rectus abdominis which it innervates, in addition to giving off cutaneous branches which go through the muscle or are given off at its lateral or medial border, near the cranial border of the umbilicus. The nerve takes part in the innervation of the mammary glands and the Mm. praeputiales craniales. In one of the specimens, the last thoracic nerves had communicating fibers with the first lumbar spinal nerves. Each of these ran very close to the body of the vertebra and joined the first lumbar nerve at its exit from the intervertebral foramen.

The first lumbar spinal nerve (L₁)

The ventral branch of the first lumbar spinal nerve contributes a small branch to the second lumbar spinal nerve before the former divides into two main branches near, or at, the lateral border of the M. quadratus lumborum. It courses under the transverse process of the succeeding vertebra, running caudally, laterally and ventrally, and its two branches accompany the two caudal branches of the A.

phrenico-abdominalis. The short, cranial branch runs laterally, supplies innervation to the M. obliquus externus abdominis, and sends out a branch to the skin, about one third of the way down the flank. The longer, caudal branch passes inwards and assumes a course between the M. obliquus internus abdominis and the M. transversus abdominis, giving branches to both of these muscles and continuing between the M. transversus abdominis and the peritoneum to the lateral border of the M. rectus abdominis, at which point it gives off a cutaneous branch while the main trunk continues in the substance of the muscle towards the median plane, and behind the umbilicus. It also innervates the mammary glands in this region.

The second lumbar spinal nerve (L₂)

Immediately on its exit from the intervertebral foramen the ventral branch of the second lumbar spinal nerve, in most cases, divides into two branches, which are cranial and caudal in position. The cranial branch receives the contribution from the first lumbar spinal nerve, as indicated above, and subdivides into branches, which are again cranial and caudal in disposition. The cranial subdivision appears to take the whole of the contribution from the first lumbar nerve, passes ventrolaterally and gives off a cutaneous branch and a muscular branch to the M. obliquus externus abdominis. The caudal subdivision passes caudoventrally

between the *Mm. obliquus internus abdominis* and *obliquus externus abdominis*, furnishes them twigs, and gives off a branch which innervates the *M. cutaneus trunci* and the skin.

The primary caudal branch of the second lumbar spinal nerve also subdivides into two branches which are cranial and caudal in position. The cranial subdivision, after traversing caudal along the dorsal aspect of the *M. psoas major* for a distance of one and one-half vertebrae, divides at the lateral border of that muscle into a shorter cranial and a longer caudal branch. The former branch accompanies the middle branch of the *A. phrenico-abdominalis*, and runs through the abdominal wall, giving off branches, first to the *M. transversus abdominis*, and then to the *M. obliquus externus abdominis* and ends as a cutaneous nerve. Its counterpart, the caudal subdivision, pursues a course more caudal and towards the inner or peritoneal surface of the *M. transversus abdominis*, innervating this muscle, the *M. obliquus internus abdominis*, and the *M. rectum abdominis*.

The secondary branch of the caudal primary division of the L_2 spinal nerve runs more or less parallel to the preceding branch, and more in the substance of the *M. psoas major* before emerging at its lateral border (Figure 9: 4) or, on rare occasions, piercing through the muscle emerging on its ventral surface (Figure 8: 4 and 5 and Plate 5) and the whole of it appearing to innervate the *M. obliquus internus*

abdominis which it enters at a transverse plane passing through the stifle joint, but at the iliac origin of the muscle. Sometimes the secondary branches reunite before reaching their destination and separate again in the subiliac region, one branch dividing to innervate the *Mm. obliquus internus abdominis* and *transversus abdominis*, and the other branch descending to join the lateroventral branch which continues its descent into the *M. obliquus internus abdominis*, innervating it and also giving off a cutaneous branch which appears in the inguinal region (Figure 12: 3 and 4, Figure 1: 7, Plate 8 Top).

There is a communicating branch between the ventral branches of the L_2 and L_3 spinal nerves. This communication is between the secondary branch of the L_2 and the main L_3 spinal nerves.

In four specimens (nos. 2, 4, 6, and 12) a branch from the L_2 spinal nerve either joined the L_3 spinal nerve in the formation of the *N. genitális* (*N. spermaticus externus*) in the initial course of their journey, or it sent a branch separately running alongside the *M. psoas major* to end in the *M. cremaster externus* near the internal inguinal ring (Figure 19: 3 and Figure 20: 12). In other words, a loop was formed between branches from both the L_2 and L_3 spinal nerves, the union taking place inside the substance of the *M. psoas major*, the branch from the L_3 having run in a cranial direction to meet the L_2 branch (Figure 8: 6).

The third lumbar spinal nerve (L₃)

The ventral branch of the third lumbar spinal nerve emerges from the vertebral canal between the third and fourth lumbar vertebrae. On its emergence it immediately divides into three branches. Two of these are short stems which receive the contribution from the ventral branch of the second lumbar spinal nerve and go mainly to innervate the Mm. psoas major and minor, though, as mentioned above, one of these conjoined branches may proceed either to the M. obliquus internus abdominis, or to the M. cremaster externus and the M. obliquus internus, and a twig be given off to appear in the inguinal region (Figures 7, 8, and 12). The third branch, however, courses in a medial direction, ventrally and caudally between the M. psoas major and the M. psoas minor, in a more or less horizontal fashion, until it emerges from them at the level of the fifth lumbar vertebra. Before its emergence from the muscles it gives off a proximal communicating branch to the fourth lumbar spinal nerve, and after leaving the muscles it gives off another communicating branch to the same nerve at the level of the cranial border of the transverse process of the sixth lumbar vertebra. In most cases it also receives an exchange branch from the fourth lumbar spinal nerve at the point of the distal branch contribution. In some specimens this return contribution was missing on one side and, rarely, on both sides. Here again,

in some cases, the arrangement was more plexiform than a few simple communicating branches.

Immediately after, or before, the above arrangement, the third lumbar spinal nerve, now called the N. spermaticus externus, or appropriately the N. genitalis, divides into two branches, one of which receives a communicating branch from the fourth lumbar spinal nerve. The two divisions unite after enclosing the deep circumflex iliac vessels and continue caudoventrally with the external iliac vessels, parting with them at the origin of the pudendo-epigastric vascular trunks which they now follow to the internal inguinal ring. Here the stem splits into two branches which in turn subdivide into two each, or one subdivides and the other remains single. Two of the four, or one of the three, branches enter the M. obliquus internus abdominis and the pubic tendinous attachment of the M. rectus abdominis. The remaining two branches follow the external pudental vessels. One of them gives off a twig to the M. cremaster externus, and in the male it supplies innervation to the tunica vaginalis, the inguinal fascia, prepuce, Mm. praeputiales caudales (Figure 3: 5, 8) and cranial part of the scrotal fascia and skin, and were seen to intermingle with the terminal branches of the Nn. scrotales caudales, while in the female the two branches descend into the inguinal region where they branch to supply the mammary glands located here. The nerves, on emerging

from the external inguinal ring, consistently pass through and innervate the superficial inguinal lymph node, Figures 13: 3, 5; 20: 13. In many cases branches of the N. cutaneus femoris lateralis reached the inguinal region and innervated the area lateral to the superficial inguinal lymph nodes, and thus came in contact with the foregoing nerves.

The fourth lumbar spinal nerve (L₄)

The ventral branch of the fourth lumbar spinal nerve emerges as a single stem from the intervertebral foramen between the fourth and fifth lumbar vertebrae. It courses alongside the body of the fifth lumbar vertebra, in a caudoventral direction, pierces between the M. psoas major and M. psoas minor, and emerges from them at the level of the caudal end of the fifth lumbar vertebra. The nerve divides into two branches while still inside the substances of the two previously named sublumbar muscles. The cranioventral nerve receives the proximal contributory branch from the third lumbar spinal nerve, and, immediately on leaving the muscles, receives the distal contributory branch from the third lumbar spinal nerve now called the N. genitalis. It is here that it also contributes a twig from its cranioventral branch back to the N. genitalis. From here the main branch of the fourth lumbar spinal nerve passes laterally, ventrally and caudally, obliquely crosses the caudal third of the M. psoas major and M. psoas minor and the origin of the M. iliacus at the level

of the tuber coxae, pierces the coxal origin of the M. obliquus internus abdominis, or it may course between the caudal border of the muscle and the os ilium, and gains the deep face of the M. tensor fasciae latae, descends along this surface of the muscle together with the descending branch of the A. circumflexa ilium profunda and its satellite veins. Just at its entrance into the M. obliquus internus abdominis it divides into two equal branches, which also subdivide to make four branches in all. Two of the subdivisions run in front of the thigh and stifle joint bearing to the lateral aspect of the thigh as far down the middle third of the leg as the cutaneous nerve. The two remaining branches run towards the inguinal region and along the mammary line and prepuce. Some twigs run horizontally forwards together with the terminal branches of the deep circumflex iliac vessels which appear in the fold of the flank (Figure 12: 5, 13: 4, Plate 8 Top).

One of the primary branches has a short course, as it joins the succeeding ventral branch of the fifth lumbar spinal nerve along the body of the sixth lumbar vertebra, although its fibers are quite apparent as they continue in the N. obturatorius in all cases.

The ventral branch of the L₄ spinal nerve not only constitutes the main root of the N. cutaneus femoris lateralis, but also concurs in the formation of the Nn. femoralis and

obturatorius. It also contributes many branches to innervate the Mm. psoas major and minor. On some occasions it receives a small contribution from the second lumbar spinal nerve (Figure 1: 10, 4: 3, 5: 5).

The fifth lumbar spinal nerve (L₅)

The ventral branch of the fifth lumbar spinal nerve is much larger than the preceding four nerves. It is the main constituent of the N. femoralis although the fourth lumbar spinal nerve appears, on several occasions, to be somewhat the same size in forming that nerve. This was observed in all specimens with six pairs of lumbar spinal nerves, but in the one in which the lumbar nerves were reduced to five pairs, the fourth took over the lead, while the fifth went to join the sacral spinal nerves as well as contributing to the N. obturatorius.

Contributory branches from the ventral branches of the L₃ and on rare occasions of the L₆, add to the bulk of the N. femoralis, and in the same way the N. obturatorius, whose origins are almost identical with those of the N. femoralis, (Figures 1, 2, 3, 4, 5, 11, 13, 16, 17, 19, 20, and 21, Plates 1 and 13).

It lies very close to the body of the sixth lumbar vertebra as it passes caudoventrally, then inclines latero-caudally through the substance of the M. iliacus as part of the N. femoralis which will be described later. The branch

from the preceding lumbar nerve joins this one at the cranial third of the sixth lumbar vertebra, while its contribution to the sixth lumbar nerve joins the latter at the promontory of the sacrum, and/or in some cases, it also received a contribution from the sixth lumbar spinal nerve (Figure 19: L₅, L₆).

The sixth lumbar spinal nerve (L₆)

The ventral branch of the sixth lumbar spinal nerve, constituted the last lumbar nerve in all cases (except one in which the fifth was the last) (Figure 4). Like the preceding nerve, it lies quite close to the vertebral body as it proceeds caudally to cross alongside the promontory of the sacrum on which there is a deep notch in which the nerve lies. It is at this point that the contributions from the preceding nerves join it. As it approaches the caudal end of the first segment of the sacrum, it is joined by the ventral branch of the first sacral spinal nerve, forming a flattened trunk which is joined later by a small contribution from the ventral branch of the second sacral spinal nerve. It is one of the main cores of the Nn. ischiadicus and glutaiei, and is seldom a contributor to the Nn. femoralis and obturatorius.

In some cases, the sixth lumbar and first sacral spinal nerves show some interchange of fibers in forming the Nn. ischiadicus and glutaiei (Figure 5: 15, 16).

The first sacral spinal nerve (S₁)

The ventral branch of the first sacral spinal nerve is most commonly the central core of the N. ischiadicus, although in some cases many of the first sacral fibers go into the formation of the Nn. glutaeeus cranialis et caudalis, pudendus and pelvinus (See Table 1, which shows how the various peripheral nerves derive their fibers).

The ventral branch of the first sacral spinal nerve leaves the vertebral canal through the first ventral sacral foramen, as a conspicuously large cord. It is directed caudolaterally along the ventral surface of the respective vertebra. At the mediocaudal border of the wing of the sacrum opposite to the greater sciatic foramen the first sacral receives the ventral branch of the last lumbar nerve, which already includes fibers from the ventral branches of the preceding two, or at least one, lumbar spinal nerves. Here it also joins the ventral branch of the second sacral spinal nerve, blending to produce a sort of plexus which gives rise to the N. ischiadicus and Nn. glutaeei. The internal iliac vessels run on the ventral aspect of these nerve roots, as they all course towards the foramen ischiadicum majus.

The contribution from the second sacral nerve to the first one appears to be given away almost wholly from the N. ischiadicus to the N. pudendus, joining the latter at the

F. ischiadicum minus, this being done through a constant communicating branch between the N. ischiadicus and N. pudendus (Figure 1: 16, 5: 19). This communicating branch was found in all of the specimens examined.

The second sacral spinal nerve (S₂)

The ventral branch of the second sacral spinal nerve emerges through the ventral foramen of the sacrum between the second and third sacral segments. It divides at its exit into two branches, one of which, usually the larger, joins the ventral branch of the first sacral spinal nerve, apparently to form the N. ischiadicus; but closer examination shows it sending some fibers to the Nn. glutaeci and N. pudendus. The second branch subdivides into two, and sometimes more, branches; one of these joins with a branch from either the first or third sacral spinal nerve, in the formation of the N. splanchnicus pelvinus which participates in the formation of the Plexus pelvinus. The other branches commonly join the ventral branch of the third sacral spinal nerve to form the N. pudendus or by-pass it as the N. cutaneus femoris caudalis, or as part of the nerve to the M. coccygeus (Figures 1: 17; 2: 11, 12, 13; 3: 13, 15; 11: 4, 5; Plate 1: 12, 13).

In one case, the S₂ spinal nerve had contributed the larger root to the N. pudendus, and in eight cases its contribution to that nerve was the same size as the contribution

from the S₃ spinal nerve.

The third sacral spinal nerve (S₃)

The ventral branch of the third sacral spinal nerve is much reduced in size in comparison to the preceding sacral branches. It emerges from the sacral canal in the corresponding ventral foramen between the third and fourth sacral segments. It showed itself to be the outstanding root of the N. pudendus in two-fifths of the cases, and equal in size to the S₂ spinal nerve root in slightly more than half of the cases, about 54 percent, whereas in one case out of fifteen examined it was negligibly small. In a few cases the S₃ spinal nerve sent a twig to join the fourth sacral spinal nerve, and a little less frequently the fourth sacral spinal nerve appeared to have contributed a branch that joined the S₃ spinal nerve (Figures 3, 4, 12, 16, 17). In some cases the nerve to the M. coccygeus sprang from the S₃ spinal nerve as the latter had just emerged from the sacral canal, but mostly, it was given off from the N. pudendus after all contributions had merged (Figure 22: 8, 15; Plate 12). Cases were noted, in which fibers from the S₃ and S₂ nerves coursed together as the N. cutaneus femoris caudalis through the sacro-sciatic attachment of the M. biceps femoris and M. semitendinosus.

As has already been indicated above for the S₂ spinal

nerve, the S_3 spinal nerve contributes a branch to the N. splanchnicus pelvinus.

The fourth sacral spinal nerve (S_4)

The ventral branch of the fourth sacral spinal nerve emerges through the intervertebral foramen between the sacrum and the first coccygeal vertebra. It is the smallest of the ventral branches of the sacral spinal nerves. In most cases this nerve, after detaching a twig to the M. sacrococcygeus ventralis, runs caudally and ends by innervating the M. sphincter ani externus, M. levator ani and the anal skin. In three specimens it sent a small branch which joined the S_3 to form the N. pudendus. One other mode of disposition of this nerve is that it receives a branch from the N. pudendus, and the trunk so formed goes to innervate the Mm. sphincter ani externus, levator ani, and the anal skin. Still another form of distribution of this nerve is that it sent off a branch which joined the Nn. spinales coccygei with which it was distributed to the muscles of the tail (Figures 1: 19; 2: 14; 3: 16; 4: 11; 5: 25; 11: 7; 12: 18; Plate 1: 15).

The coccygeal spinal nerves (C_y)

The ventral coccygeal spinal nerves were observed to vary from four to six pairs. They emerged through the intervertebral foramina distal to each of the first four or six coccygeal vertebrae. They joined in the formation of the

coccygeal nerve trunks alongside the ventral tubercles of the coccygeal bodies, being covered by the Mm. sacrococcygeus ventralis medialis et lateralis. They innervated these muscles as well as the Mm. intertransversarii ventralis et dorsalis caudae. The first pair often received a branch from the S₄ spinal nerve, and it was observed in one of the specimens to have detached a small branch to join that nerve of the S₄ which innervated the Mm. sphincter ani externus, levator ani, and the anal skin.

At each coccygeal segment there was a branch passing dorsally to join a corresponding branch from the dorsal coccygeal nerve trunk.

The Lumbosacral plexus (Plexus lumbosacralis)

In light of the above observations, it seems evident that the first four ventral branches of the lumbar nerves are most responsible for the innervation of the operational area in the flank, although in some cases the fourth nerve may be limited to the thigh region.

The lumbosacral plexus has been observed as being formed by the ventral branches of the last four lumbar spinal nerves and the first three sacral spinal nerves, and in rare cases include the fourth sacral nerve.

As was noted above on the individual nerves furnishing communicating branches to their successive neighbors in the initial stages of their courses, one is inclined to say that

all of the lumbar and sacral spinal nerves join in the formation of the lumbosacral plexus. But as the plexus in question is taken to comprise the nerves which have the direct responsibility of innervating the structures of the pelvic limb, then the first statement furnishes the accent to the lumbosacral plexus.

It was noted in 8 out of 15 specimens that the ventral branch of the L_3 spinal nerve detached a branch which bridged over the medial aspect of the L_4 spinal nerve and continued into the N. obturatorius, and thus this latter nerve is included in the formation of the lumbosacral plexus (Figures 4: 5; 16: 7).

As mentioned previously, Reimers (1913) described the lumbar and sacral plexuses independently. Ellenberger and Baum (1943) state that the lumbosacral plexus is formed by the last three lumbar and first two sacral nerves, while Sisson and Grossman (1953) do not include the second sacral, but agree with Ellenberger and Baum on the lumbar roots. Chauveau and Arloing (1902), on the other hand, take into consideration the last two lumbar and first two sacral nerves, but included the last lumbar root as a sacral one.

Nerves Emanating from the Lumbosacral Plexus and Those Preceding it

The first two lumbar nerves are included with the nerves which precede those forming the lumbosacral plexus. These

nerves are considered as not taking part in the lumbosacral plexus, although indirectly they do so through the medium of their inconstant communication with each other and with the succeeding nerves. Their courses and branches have been described already. It is now appropriate to consider them as named entities.

N. iliohypogastricus

The ventral branch of the first lumbar spinal nerve (L_1) is the N. iliohypogastricus. But when there are seven lumbar nerves, as recorded in the existing textbooks (Ellenberger and Baum, 1943; and Reimers, 1913), the first lumbar nerve takes the name N. iliohypogastricus cranialis, as is also recorded for the dog (Miller, Christensen and Evans, 1964) and for the cat and rabbit (Langley and Anderson, 1895).

In the present investigation, a case was encountered in which the number of lumbar spinal nerves had been reduced to five pairs. This meant that the N. iliohypogastricus was missing anatomically, but functionally the last pair of thoracic nerves was found to be distributed in exactly the same way as the N. iliohypogastricus of the specimens which had six pairs of lumbar nerves (Figure 4: Th). Reimers (1913) noted that the reduction from seven to six pairs of lumbar spinal nerves, and the thoracic spinal nerve increasing the series in the thoracic region was termed the N. thoracalis accessorius.

N. ilioinguinalis

The ventral branch of the L_2 spinal nerve, is the N.

ilioinguinalis. In most cases, it was seen to divide and subdivide making up to four branches which innervated the abdominal muscles as well as the fascia in the inguinal region and skin of the flank, mammary glands and prepuce.

In two of the examined specimens, it formed a sizeable contribution to the N. genitalis (N. spermaticus externus) (Figure 4: 2 and 5). But one of these was the specimen in which the lumbar spinal nerves had been reduced to five pairs. In several cases, one of its branches joined with a branch given off by the L₃ spinal nerve to form, what appears to be, a special nerve running along the lateral border of the M. psoas major and entering either the M. obliquus internus or the M. cremaster externus or dividing to innervate the two muscles at the same time (Figures 17: 2; 19: 3; 21: 3).

The two foregoing lumbar spinal nerves are the main nerves which supply the abdominal wall, especially the area caudal to the umbilicus and craniomedial to the thigh. It is in this area also that the N. genitalis and the N. cutaneus femoris lateralis join in.

The nerves considered to arise from the lumbosacral plexus are: the N. genitalis (N. spermaticus externus), N. cutaneus femoris lateralis, N. femoralis, N. obturatorius, N. glutaesus cranialis, N. glutaesus caudalis, N. ischiadicus, N. cutaneus femoris caudalis, N. splanchnicus pelvinus, N. pudendus, N. rectalis caudalis (N. haemorrhoidalis caudalis),

and, indirectly, the Nn. perineales profundus et superficialis, N. rectalis medius, Nn. scotalis caudalis et medius, N. labialis, N. dorsalis penis, and N. clitoridis. All of the indirect group have a tendency to be branches of the N. pudendus, and are therefore furnished somewhat by roots similar to those which give rise to the N. pudendus.

N. genitalis (N. spermaticus externus)

The N. genitalis arises most of the time from the ventral branch of the L₃ spinal nerve, being reinforced by a twig from the ventral branch of the L₂ spinal nerve in a few cases, and most constantly by a contribution from the ventral branch of the L₄ spinal nerve. In the specimens examined, the frequency of its deriving roots as mentioned above was as follows: In one case it was formed by the ventral branches of the L₂ and L₃ spinal nerves; in two cases it was formed by the ventral branches of the L₂, L₃ and L₄ spinal nerves; in twelve cases it was formed by the ventral branches of the L₃ and L₄ spinal nerves. In all cases, except the one in which it was formed by the L₂ and L₃ spinal nerve, the largest contribution was from the ventral branch of the L₃ spinal nerve. In the exception given the ventral branch of the L₂ spinal nerve was the main root, and that of the L₃ nerve was just contributory (Figures 1, 2, 3, 4).

The N. genitalis courses between the sublumbar muscles, Mm. psoas major et minor, from which it emerges at the caudal

third of them, about the level of the fifth lumbar vertebra. In this position it is related to the N. cutaneus femoris lateralis which lies caudal to it between the two muscles. While inside the substance of these muscles it detaches a small branch to the N. cutaneus femoris lateralis, on emerging out of the muscles it detaches another branch to the same nerve, and it also receives a branch from the N. cutaneus femoris lateralis. At this point, or before, it divides into two branches, both of which cross over the medial aspect of the N. cutaneus femoris lateralis, but separate to enclose the deep circumflex vessels after which they may join up again, and, subdividing into four branches, one of which innervates the M. cremaster externus. The second branch may terminate in the tendon of insertion of the M. rectus abdominis in the female, and in the male continues into the tunica vaginalis and scrotal fascia. Of the remaining two branches, one innervates the M. obliquus internus abdominis, while the other continues as the N. inguinalis in the inguinal canal to ramify in the inguinal region innervating the superficial inguinal lymph node, mammary gland in the female, and M. praeputialis caudalis and the prepuce in the male (Figures 1: 9, 9', 9", 9''' ; 2: 1, 3, 4; 3: 5,7,8; 4: 2; 5: 4). While crossing the region of the inguinal lymph node the branches of this nerve penetrate the body of the lymph node to appear as if they were its lymph vessels.

N. cutaneus femoris lateralis

This nerve had similar origins as the preceding, but its main root was the ventral branch of the L₄ spinal nerve, except in that specimen in which the lumbar nerves had been reduced to five pairs, in which case the L₃ spinal nerve took the lead, and was supported by the L₂ spinal nerve only. So the distribution was as follows: In one specimen this nerve was formed by the ventral branches of the L₂ and L₃ spinal nerves; in one specimen it was formed by the L₂, L₃, and L₄ nerves; in the rest of the specimens this nerve was formed by the L₃ and L₄ spinal nerves. The course of the N. cutaneus femoris lateralis is at first parallel to that of the N. genitalis in that they both lie in the interstices of the Mm. psoas major et minor where it receives the contribution from the N. genitalis and emerges from the muscle a little caudal to the preceding nerve. On leaving the muscle the N. cutaneus femoris lateralis receives another contributory branch from the N. genitalis, passes lateral to it and bends sharply ventrally and laterally at the level of the tuber coxae, penetrates the coxal attachment of the M. obliquus internus abdominis, or between it and the M. iliacus, and gains the medial surface of the M. tensor fasciae latae, under which it descends, together with the descending branch of the deep circumflex iliac artery. It divided into two branches, then subdivided to produce four branches which were distributed

as previously described (Figures 1: 6, 6'; 12: 5; Plates 1 and 8). However, two of the branches course cranial to the thigh region as they continue downwards, gain its lateral aspect and reach the leg just below the stifle. The other two branches bear a course towards the inguinal region and also send branches cranially in the fold of the flank, being interspersed with the terminal branches of the deep circumflex artery. They innervate the subiliac lymph nodes in addition to the skin of the area.

N. femoralis

The N. femoralis arises from several roots as will be shown by the following recordings: In one case, in which the lumbar spinal nerves were reduced to five pairs only, it was found to arise from the ventral branches of the L₃ and L₄ spinal nerves; in seven cases it was formed by the ventral branches of the L₃, L₄ and L₅ spinal nerves; in four cases it was formed by the ventral branches of the L₄ and L₅ spinal nerves; and in three cases it was formed by the ventral branches of the L₄, L₅ and L₆ spinal nerves. In all, except one case, it had the L₅ spinal nerve as its main root. In the exception indicated the L₄ spinal nerve was the main root. In the three cases in which the L₆ spinal nerve took part in the formations of this nerve, only a very small twig was found in each case.

The nerve takes an oblique course as it leaves the body

of the sixth lumbar vertebra running laterally, and caudo-ventrally, at first being covered by the M. psoas major on its ventral aspect, later by the M. iliacus in which the nerve becomes deeply buried until it leaves the muscle about the middle of the shaft of the ilium where the nerve crosses over the lateral aspect of the inguinal ligament. Here it lies at the caudal border of the origin of the M. rectus femoris, medial to the origin of the M. vastus medialis and lateral to that of the M. sartorius. Along this course, extending from the cranial end of the sacrum, the course of the N. femoralis is parallel to that of the external iliac vessels on its medial aspect, although the nerve is inside the above-mentioned muscles. Just before dipping in between the Mm. sartorius, vastus medialis and rectus femoris, the N. femoralis detaches the N. saphenus. The latter nerve descends on the medial surface of the M. vastus medialis under cover of the M. sartorius and emerges from the muscles at the middle third of the thigh. The N. saphenus gives off a branch to the M. sartorius at its proximal end, but in some cases this nerve branch arises directly from the N. femoralis, although in one case it was also found to receive innervation from the N. obturatorius before the latter nerve bent into the obturator foramen. The course of the N. saphenus now lies between the Mm. sartorius and vastus medialis, and it begins to divide into radiating branches, innervating the skin on

the medial aspect of the stifle region and the leg. The N. saphenus, in one case, was seen to form a sort of plexus on the A. saphenus while still under cover of the M. sartorius.

The N. femoralis, on entering into the space between the Mm. rectus femoris and vastus medialis, immediately divides into branches which innervate these muscles as well as the other muscles of the quadratus group. In its proximal part, it gives off about four to six muscular branches to the M. Psoas minor and M. iliopsoas.

N. obturatorius

This nerve has almost exactly the same roots of origin as the N. femoralis, as the following figures will show: In one case it was formed by the ventral branches of the L₃ and L₄ spinal nerves; in six cases it was formed by the ventral branches of the L₃, L₄ and L₅ spinal nerves; in one case it was formed by the ventral branches of the L₃, L₄, L₅ and L₆ spinal nerves; in two cases it was formed by the ventral branches of the L₄ and L₅ spinal nerves; and in five cases it was formed by the ventral branches of the L₄, L₅ and L₆ spinal nerves. It was the ventral branches of the L₄ and L₅ nerves which formed the outstanding contributions to the N. obturatorius, the other roots giving only small twigs to it. It was in the specimen with a reduced number of lumbar nerves that the L₃ spinal nerve added a large branch to the N.

obturatorius. Just as the N. femoralis was covered by the M. psoas major and M. psoas minor so also was the N. obturatorius, but the latter nerve has a course almost horizontal as it passes caudally and leaves the named muscles at the cranial end of the shaft of the ilium and lies dorsal to the tendon of insertion of the M. psoas minor. In the middle part of the shaft of the ilium it lies close to the bone until it enters the M. obturatorius internus to which it detaches two branches, or one branch which run in the same direction as the main nerve, appearing on the pelvic surface of the muscle. The parent trunk sinks into the M. obturatorius internus about the level of the pubic bone, and bonds ventrally into the obturator foramen at its cranial border, and immediately divides into several branches which innervate the Mm. obturator externus, pectineus, gracilis and adductor. As has been mentioned before this nerve was observed in one case to give off a small branch to the M. sartorius before it crossed over the pubis.

N. glutaesus cranialis

This is one of the nerves whose fibers of origin are so intertwined with those of the N. ischiadicus and N. glutaesus caudalis that the roots given from the standpoint of a gross study may not be correct and should be verified by electrical stimulation. However, separation was tried as much as was

practicable, and the following roots recorded: In one case it was found to arise from the ventral branches of the L₃, L₄, L₅, S₁ and S₂ spinal nerves; in one case it was from the L₄, L₅, L₆, and S₁ spinal nerves; in nine cases it arose from the L₅, L₆ and S₁ spinal nerves; and in four cases it was made up of the ventral branches of the L₅, L₆, S₁ and S₂ spinal nerves. In the specimen which had five pairs of lumbar nerves the L₃ spinal nerve participated in the formation of the N. glutaesus cranialis. The N. glutaesus cranialis does not emerge as an entity, but as part of a single plexus of which the N. ischiadicus is the most outstanding nerve arising from the plexus opposite to the greater sciatic foramen. The N. glutaesus cranialis leaves the cranioventral border of the above plexus as a very stout nerve for about 1 cm. or less, and soon divides in a radiating manner to innervate the Mm. glutaesus profundus, glutaesus medius, glutaesus superficialis, and tensor fasciae latae. The nerve of the M. glutaesus profundus runs almost horizontally along the eorsolateral surface of the muscle parallel to the lateral border of the N. ischiadicus and appears to be given off by the latter nerve (Figure 12: 7). The nerve to the M. tensor fasciae latae passes either between the ilium bone and the M. glutaesus profundus or between that muscle and the M. glutaesus medius pars accessorius, and reaches the M. tensor fascise latae (Figure 15: 10; Plate 9).

N. glutaesus caudalis

This nerve is one whose fibers are in a sort of common weave with the preceding nerve and the N. ischiadicus. In fact, it could be described as a branch of the N. ischiadicus. Nevertheless, tracing the fibers which constitute the N. glutaesus caudalis the following roots were observed: In one case it was formed by the ventral branches of the L₃, L₄, L₅ S₁ and S₂ spinal nerves (Specimen no. 4); in one case it was formed by the ventral branches of the L₅, L₆ and S₁ spinal nerves (Specimen no. 9, Figure 12); in ten cases it was formed by the ventral branches of the L₅, L₆, S₁ and S₂ spinal nerves; and in three cases the nerve was formed by the ventral branches of the L₆, S₁ and S₂ spinal nerves.

The N. glutaesus caudalis is separated from the previously mentioned plexus in various ways. In most cases this occurs by means of two strands which appear to be detached from the N. ischiadicus before the latter gives off a communicating branch to the N. pudendus (Figures 2: 9; 3: 24; 10: 2). Less frequently, the N. glutaesus caudalis parts with the said communicating branch (Figure 12: 9) and in some cases it has a branch preceding the communicating one, and another branch after it (Figure 15: 3). In other cases, it may run as one trunk with the N. cutaneus femoris caudalis, the two nerves separating in the region of the tuber ischii -- the N. glutaesus caudalis entering the Mm. semitendinosus and biceps

femoris, and the N. cutaneus femoris caudalis penetrating between these two muscles and innervating the skin above their proximal attachment towards the buttocks (Plate 1: 10).

N. ischiadicus

This is the largest of the nerves lying in the gluteal region. It forms a flat band over the femoral part of the M. gluteus profundus and traverses caudally over the Mm. gemelli, quadratus femoris, and adductor. It separates into its two terminal branches, the N. tibialis and N. fibularis, about the middle of the thigh.

The N. ischiadicus derived its fibers in the following manner: in one case the nerve was formed by the ventral branches of the L₃, L₄, L₅, S₁ and S₂ spinal nerves, and in eleven cases it was formed by the ventral branches of the L₅, L₆, S₁ and S₂ spinal nerves. In the cases where the origin of this nerve included the L₃ spinal nerve, the lumbar spinal nerves were reduced to five pairs only in one case, and in the other case the L₃ spinal nerve had bridged so much onto the succeeding lumbar nerves that it might have fibers crossing together with the ones credibly forming the N. ischiadicus.

After the branches converge, about the caudal end of the first segment of the sacrum (including those fibers which form the N. gluteus cranialis and N. gluteus caudalis) they

head caudolaterally and ventrally to gain the greater sciatic foramen, where the *N. glutaesus cranialis* separates from the trunk (in some cases, one of the two, or sometimes three, components of the *N. glutaesus caudalis*, separates here also). The main *N. ischiadicus* continues as a flat band on the surface of the *M. glutaesus profundus*, courses over the *Mm. gemelli* and then over the *M. quadratus femoris* as it bends ventrally at the medial aspect of the trochanter major.

In addition to parting with the *Nn. glutaci*, it gives off the following branches in succession: 1. A constant communicating branch is given off to the *N. pudendus* at the caudal limit of the greater sciatic foramen and runs along the dorsal border of the *M. glutaesus profundus*, gaining entrance between the *A. and V. iliacs interna* -- the artery being on its dorsal aspect and the vein ventral. The branch thus reaches the lesser sciatic foramen where it joins the *N. pudendus*. This branch has been found to alternate with that of the *N. glutaesus caudalis* as described previously. 2. At the level of the trochanter major it gives off a large branch which supplies the proximal parts of the *M. biceps femoris* and *semitendinosus*. 3. Sometimes, also, the *N. cutaneus femoris caudalis* takes origin here to supply the skin just above the proximal attachment of the *Mm. biceps femoris* by passing between them. 4. At the ventral aspect of the main nerve branches are given off to innervate the *Mm. gemelli* and *M. quadratus femoris*. 5. Slightly lower down on the

thigh a large muscular branch is given off to innervate the Mm. biceps femoris (middle part), semitendinosus, semi-membranosus, pectineus and adductor. 6. A branch is given off to innervate the distal part of the M. biceps femoris. This branch has a sizeable twig which penetrates the center of the muscle and innervates the skin on the lateral aspect of the thigh near the distal attachment of the M. biceps femoris.

After all branches to the muscles in the thigh region have been given off, the parent trunk of the N. ischiadicus terminates by dividing into the N. tibialis and N. fibularis (N. peroneus). The entire course of these latter nerves is beyond the scope of this present investigation, but their locations in the thigh are given below.

In the undisturbed state, the parent nerve terminates in the middle of the thigh. The apparent commencement of the two terminal branches of the N. ischiadicus appears to be at the junction of the middle and distal thirds of the thigh, which is marked by the caudal curvature of the M. gastrocnemius, the lateral head of which wedges between the two nerves. But cleaning of the area shows the branching to commence even higher up at the proximal end of the thigh, at the level of the hip joint or even above it. The N. tibialis lies more medial and somewhat caudal while the N. fibularis lies craniolateral in position. The N. tibialis descends and dips in between the two heads of the M. gastrocnemius and

continues its course in the leg. The N. fibularis courses on the lateral aspect of the proximal part of the lateral head of the M. gastrocnemius in a line approximately parallel with the femur when the animal is standing, so as to lie obliquely as it crosses the M. gastrocnemius. The nerve dips between the M. gastrocnemius and the M. soleus to gain the cranial surface of the leg, where it continues its course. At this point the nerve is about a hand breadth distal to the stifle joint.

Just at the point of separation of the Nn. tibialis and fibularis, two, and rarely three, branches arise. The third rarer one, usually given off by the N. fibularis, passes laterally and pierces the distal end of the M. biceps and ends in the skin on the lateral aspect of the leg. One of the more common branches receives a large twig from the N. tibialis and a smaller one from the N. fibularis, follows a course directly caudad, being accompanied by the A. and V. femoris caudalis in the space between the Mm. biceps femoris and semitendinosus, and innervates the skin at the caudal aspect of the leg as the N. cutaneus surae caudalis (medialis). The other of the common branches receives a large contribution from the N. fibularis and only a small contribution from the N. tibialis, and runs along the caudal border of the lateral head of the M. gastrocnemius under cover of the M. biceps femoris, penetrating the aponeurotic attachment of the latter muscle to end in the skin of the caudolateral aspect

of the leg as the N. cutaneus surae caudalis lateralis (Figure 14 and 15: 8 and Plate 1: 21 and 8 Top).

N. aplanchnicus pelvinus

This is a nerve belonging to the sacral outflow of the parasympathetic part of the autonomic nervous system. In the present examination it arose in the following manner: In three cases it was formed by the ventral branches of the S₁ and S₂ spinal nerves; and in twelve cases it arose from the ventral branches of the S₂ and S₃ spinalnerves. At its beginning it is under cover of the M. sacrococcygeus ventralis lateralis. Its course and distribution are described under the autonomic nervous system.

N. pudendus

This is a nerve which derives its fibers from all of the ventral branches of the sacral region, even though it does not do so at all times and in all specimens. It was found to do this in the following manner: In one case it was formed by the ventral branches of the S₁, S₂ and S₃ spinal nerves, in eleven cases it was formed by the ventral branches of the S₂ and S₃ spinal nerves, and in three cases it was formed by the ventral branches of the S₂, S₃ and S₄ spinal nerves. In eight specimens, the S₂ and S₃ spinal nerves contributed equally to the nerve; in six cases only the S₃ spinal nerve had a major contribution, while in one case the

S₂ spinal nerve contributed almost all the fibers to this nerve (Specimen no. 9, Figure 13: 11).

The N. pudendus, after the joining of its roots, lies on the deep face of the sacrospinotuberal ligament, being covered by the M. obturator internus. The nerve enters the texture of the ligament and traverses in it for a short distance, leaving it near the lesser sciatic foramen. Here it is joined by a communicating branch from the N. ischiadicus. The trunk thus formed divides into four branches, two smaller, and two larger ones. Sometimes, the nerve divides into two equal branches which subdivide into two each or, in some cases into smaller branches, which ultimately end in various nerves innervating the structures in the perineum, including the mammary gland in the female, and scrotum in the male. Inside the pelvis it detaches a branch to the M. occygeus. This branch may run at the edge of the M. sacrococcygeus ventralis or in its substance, until it reaches its destination. Another branch given off inside the pelvis is one of the branches belonging to the N. cutaneus femoris caudalis, whose fibers come from either the S₁, S₂ or S₃ spinal nerves, which join to form one nerve, or run in separately, inside the sacrospinotuberal ligament, only to leave the ligament, passing out between the Mm. biceps femoris and semitendinosus to innervate the skin above their proximal attachment. In some cases, these branches come off from the N. pudendus near the

communication from the N. ischiadicus at the lesser sciatic foramen. In rarer cases, the N. cutaneus femoris caudalis came off from the N. pudendus after receiving the communication from the N. ischiadicus, or came from the branch itself. This was found in those cases in which the N. glutaenus caudalis also contained fibers which included those which innervated the part of the skin normally innervated by the N. cutaneus femoris caudalis.

The following nerves from the conjoined trunk at the lesser sciatic foramen arise in turn. N. perinealis superficialis, N. perinealis profundus, N. dorsalis penis, N. clitoridia, N. mammarius caudalis or N. scrotalis caudalis, depending on the sex of the individual, and the N. labialis.

The N. perinealis superficialis leaves the parent nerve at the lesser sciatic foramen and follows along the medial aspect of the tuber ischii, passing through the attachment of the sacrospinotuberal ligament at this point, and gains the ischioanal fossa, where it divides into two branches, one of which, the N. labialis, courses to the anal aspect ending in the skin (Figure 10: 7 and 8). The other branch, the N. scrotalis caudalis, bears more to the limb aspect arborizing in the skin caudal to the M. semimembranosus and partly in the lateral part of the scrotum, or of the vulva (Figure 12: 17).

The N. perinealis profundus may arise from the same trunk with the N. perinealis superficialis, from which it

separates to innervate the striated muscles of the perineum (*M. sphincter ani externus*, *M. levator ani*, *M. constrictor vulvae*, *M. ischiocavernosus*, and *M. bulbocavernosus*). These muscles may also receive separate branches from the continuing trunk of the *N. pudendus*, but all are included in the name *N. perinealis profundus*. A branch always coursed from the *N. pudendus* in a cranial direction in both sexes, and supplied the *M. urethralis* and *M. constrictor vaginae* (vestibuli). In many cases this branch continued towards and appeared to take part in the formation of the pelvic plexus. The course of this branch is along the urogenital tract (Figure 2: 20; 5: 20; 18: 16).

The *N. pudendus* continues its course inclining to the ischial arch, the right and left nerves being close together in the midline, but separated by an elastic sheet of fascia which fixes the penis in this region. The nerves pass on either side of the urethra, at the bend it makes at the ischial arch and each gains the dorsal surface of the root of the penis as the *N. dorsalis penis*, until the dorsal bend of the sigmoid flexure where they both incline to one side (Figure 13: 14, Plate 8 Bottom). From here it is interesting to note that each nerve takes a course which is no longer dorsal. Shortly after crossing the sigmoid flexure, each nerve divides into two branches which wind themselves onto the body of the penis as they proceed towards its preputial end. The course of the nerves is spiral following the general spiral

nature of the body of the penis.

Each nerve gives off two branches near the ischial arch. One of these branches enters the M. ischiocavernosus, while the other one descends by the side of the sigmoid flexure and gains the interscrotal fascia onto which it spreads out as the N. scrotalis medius (Figure 13: 13 and Plate 8: 5 Bottom). Near the sigmoid flexure, the N. dorsalis penis gives off a branch which subdivides to innervate the fascia enveloping the penis and the distal part of the M. retractor penis (Figure 13: 16; 18: 20).

In the female, the N. pudendus terminates near the ischial arch by dividing into two branches, the N. clitoridis and the N. mammarius caudalis. The N. clitoridis is directed somewhat horizontally and caudad from the ischial arch and follows the ventral aspect of the body of the clitoris (Figure 11: 12). From this branch a twig is given off to the fascial covering of the clitoris and, in some cases, more twigs even reach the skin of the vulva (Figure 5: 29; 3: 12).

During its course the N. mammarius caudalis detaches approximately three branches which innervate the skin commencing at the ventral part of the vulva while the remaining portion of the nerve continues to the inguinal mammary glands which it innervates, hence the name.

N. rectalis caudalis

While discussing the nerves of the perineum it is appropriate to mention the N. rectalis caudalis (N. haemor-

rhoidalis caudalis). This nerve arises, in most cases, from the ventral branch of the S₄ spinal nerve. In only three cases was the S₄ observed to communicate with the S₃ spinal nerve in the formation of the N. pudendus. The N. rectalis caudalis passes caudally, being covered by the M. sacro-coccygeus ventralis, and ends in the M. sphincter ani externus and M. levator ani. In some cases a branch, the N. rectalis medius, of the N. pudendus detaches a branch which joins the N. rectalis caudalis, while in other cases the nerve passes to the same area innervated by the N. rectalis caudalis, or it may be missing as such (Figure 12: 18 and 19).

N. cutaneus femoris caudalis

This nerve has various origins, as follows: In one case it was formed by the ventral branches of the S₁ and S₂ spinal nerves; in three cases it was formed by the ventral branches of the S₁, S₂ and S₃ spinal nerves; in five cases it arose from the ventral branch of the S₂ spinal nerve, and in six cases it was formed by the ventral branches of the S₂ and S₃ spinal nerves.

In some cases, the fibers which constitute this nerve ran separately as they crossed the proximal part of the N. pudendus and entered the texture of the sacrospinotuberal ligament. They left the latter under the proximal attachment of the Mm. biceps femoris and semitendinosus between which

they emerged to supply the skin above these muscles. In other cases, the fibers joined the N. pudendus, descending with it in the ligament for a short distance after which they left as a single nerve, or in a succession of two or three branches which proceeded caudally to their destination as indicated above. This state of the N. cutaneus femoris caudalis occurs before the N. pudendus has received the communicating branch from the N. ischiadicus. In yet another form of its origin it was found to divert its direction laterally and penetrate the ligament before reaching the N. pudendus (Figures 10 and 11: 4). In the rarest cases, the N. gluteus caudalis arose, together with some fibers which were detached from it at the ischial tuberosity, to innervate the same structures described to be supplied by the N. cutaneus femoris caudalus (Plate 1: 10).

The Origin of the Lumbosacral Nerves from the Spinal Cord

As was stated in the section on materials and methods, the fifth specimen, a 6-1/2 year old sow, with 16 ribs, landrace breed, weighing 529 lbs. was examined mainly to determine the origin of the Nn. lumbales et sacrales from the spinal cord in relation to the vertebral bodies and intervertebral foramina. There were sixteen thoracic spinal nerves the last of which came out at the caudal end of the last thoracic vertebra.

There were six lumbar vertebrae and six Nn. spinales

lumbales. After removing the muscles from the vertebral column dorsally, the vertebral arches were sawed and removed to expose the spinal cord. Observations were made before and after removal of the dura mater. (Plate 3).

Before the removal of the dura mater

1. The last pair of thoracic nerves and first pair of Nn. spinales lumbales, left the cord almost opposite to the intervertebral foramina but at the caudal third of the bodies of their respective vertebrae.

2. The second and third pair of Nn. spinales lumbales left the spinal cord slightly more cranial to the cranial border of the intervertebral foramen and all were in the middle of their corresponding vertebrae.

3. The fourth and fifth pairs of Nn. spinales lumbales left the spinal cord in the cranial third of the length of their respective vertebrae.

4. The sixth pair, however, left the spinal cord at the junction of the fifth and sixth lumbar vertebrae and travelled the whole length of the sixth lumbar vertebra to its exit at the junction of the sixth lumbar vertebra and the sacrum.

5. The first pair of Nn. spinales sacrales left the spinal cord at the cranial third of the sixth lumbar vertebra.

The second pair of Nn. spinales sacrales left the spinal

cord at the middle of the sixth lumbar vertebra.

The third pair of Nn. spinales sacrales left the spinal cord at the junction of the sixth lumbar vertebra and the sacrum.

The fourth pair of Nn. spinales sacrales and all the Nn. coccygei leveled their origin from the spinal cord, within the first segment of the sacrum, but the Nn. coccygei were still matted together as they continued their course caudally to reach their respective exits.

The ganglia of the dorsal root of the spinal nerves

The spinal ganglia for the last thoracic and all the Nn. spinales lumbales and first pair of Nn. spinales sacrales were situated just at the inner edge of their respective intervertebral foramina.

The second sacral spinal ganglia were opposite to the caudal edge of the second ventral sacral foramina.

The fourth pair of sacral and all the coccygeal spinal ganglia were situated at the same level in the middle of the length of the second sacral vertebra.

After the removal of the dura mater from the spinal cord

The last thoracic and the first two lumbar nerve roots were spread more cranially than their extradural origins by 1-1/4 cm.

The roots of the third pair of Nn. spinales lumbales spread over the whole length of the portion of the vertebra

between the cranial border of their respective intervertebral foramina of exit and the cranial end of the body of their respective vertebra. The spread was more in the ventral root than in the dorsal root.

The fourth pair of Nn. spinales lumbales had its component roots extending cranially from a transverse plane passing through the middle of the transverse process of the fourth lumbar vertebra to the caudal fifth of the third lumbar vertebra.

The fifth pair of Nn. spinales lumbales had its roots occupying the whole of the middle third of the fourth lumbar vertebra, and its ventral roots were spreading 1-1/2 cm. while the dorsal ones spread for 3/4 cm. The ventral roots ended where those of the preceding pair commenced.

The roots of the sixth pair of Nn. spinales lumbales occupied the caudal third of the fourth lumbar vertebra and a cranial eighth of the fifth lumbar vertebra.

The roots of the first pair of Nn. spinales sacrales followed on immediately to occupy the succeeding one-eighth of the fifth lumbar vertebra.

The roots of the second pair of Nn. spinales sacrales through all the roots of Nn. spinales coccygei left the spinal cord immediately caudal to the roots of the first pair of the Nn. spinales sacrales in the caudal half of the fifth vertebra at evenly spaced intervals, and ended in the middle of the sixth lumbar vertebra.

From the above observation it was found that the various segments of the spinal cord for lumbar, sacral and coccygeal nerves extend from the middle of the first lumbar vertebra to the middle of the sixth lumbar vertebra. The lumbar segments end in the cranial eighth of the fifth lumbar vertebra, while the sacral and coccygeal begin here and end in the middle of the sixth lumbar vertebra.

Disposition of the Dorsal Branches of the Lumbar
and Sacral Spinal Nerves

The dorsal branches of the Nn. spinales lumbales

The disposition of the dorsal branches of the Nn. spinales lumbales et sacrales were closely examined on specimen no. 7, female (Figure 6: L₁-L₆), and a general account of them is given as it may add to the understanding of certain occurrences in innervation.

These branches were generally smaller than the ventral branches, but in some cases they attained sizes which although not making them appear larger in bulk than the ventral ones, reflected that the ventral branches looked reduced much more than they normally were.

As the whole nerve leaves the intervertebral foramen it divides into two branches, a ventral and a dorsal one. This is so in the first two nerves. In the succeeding nerves, however, the division takes place inside the vertebral canal

and the two branches run for variable distances inside the vertebral canal before gaining exit. They part immediately after leaving the intervertebral foramen and become separated by the intertransverse ligaments (Figure 6: G) over which the dorsal branches of the nerve lie.

Each dorsal branch of the *Nn. spinales lumbales* divides into two branches, a larger lateral, and a smaller medial one. The lateral branch runs laterocaudally in the *M. longissimus dorsi* giving branches to it and passes out of it at its lateral border as a cutaneous nerve. The first three of these cutaneous nerves were found to reach a plane horizontal with the stifle joint, and transverse planes passing through the caudal border of the lumbar, and cranial border of the sixth lumbar vertebra. The last three of these cutaneous nerves cover a wide area extending in a curved line through the hip joint to the stifle joint with its convexity directed caudally. (Plate 6: d.1.).

The smaller medial branches also followed a definite pattern. Each passed caudally along the vertebra under the articular process of the caudal vertebra, and ascended dorsally, meeting the dorsal branches of the *Aa. lumbalia* which pass through one or two accessory foramina. Here it divided into a number of branches most of which innervated the *M. multifidus dorsi*, and one ascended with the blood vessels along the caudal part of the spinous process, pierced

the lumbar fascia and bent laterally on the same side of the body, ran under the subcutaneous tissue caudally and ventrally to reach a horizontal line level with the tuber coxae. These cutaneous nerves were so placed that the ones which come out in the lateral branches alternated with those which ran at first in a caudodorsal direction, although they did not get to the same level under the skin. This arrangement is another explanation to the finding by Arnold and Kitchell (1957), when they were determining dermatomes of the abdominal wall of cattle.

The dorsal branches of the Nn. spinales sacrales

The dorsal branches of the Nn. spinales sacrales had an arrangement slightly different from those of the Nn. spinales lumbales. Their primary divisions are similar but their subdivisions which correspond to the lateral ones of the lumbar region were the only ones observed to have come out to the skin. The medial branches were expended in the muscles on the dorsal surface of the sacrum, and had also partly joined with the dorsal branches of the Nn. spinales coccygei, (Figure 10: 9).

The dorsal branches of the sixth N. spinales lumbalis and first N. spinalis sacralis joined to innervate the medial part of the dorsal surface of the gluteal region. The joined nerve traversed underneath the lateral part of the M. sacro-coccygeus dorsalis lateralis and emerged from it about the

middle of the gluteal region to innervate the skin of the croup (Plate 7) above the greater sciatic foramen.

The Sympathetic Nerve Trunks (Trunci sympathici)

The vertebral sympathetic ganglia in the lumbar and sacro-coccygeal regions were observed. In all of the specimens examined the ganglia were found in the middle part of the corresponding vertebral body on each side. One exception, however, was noted on the left side, where the L₂ sympathetic ganglion was at the intervertebral disc between the L₂ and L₃ vertebrae. They were lying along the medial border of the M. psoas minor, and in some cases slightly covered by the muscle in the middle part of the lumbar region. The Aorta abdominalis and the Vena cava caudalis concealed the ganglia from direct view if the vessels are not displaced. In the sacral region the ganglia were found next to the middle sacral vessels. The first pair of the sacral sympathetic ganglia was slightly away from these vessels and partly covered by the A. and V. iliaca interna. The coccygeal part was quite close to the A. and V. coccygeal mediana.

Shape and size of ganglia

Most of the ganglia in the trunks were spindle-shaped, especially in the cranial part of the lumbar and caudal part of the sacral regions including the coccygeal portion. This was especially so whenever the interganglionic fibers and the

Rami communicantes arose from the ends of these ganglia. In some cases the Rami communicantes were not only joined to the middle of the ganglia but also from both ends, thus tending to produce various shapes -- triangular, stellate and quadrangular, as also found by Uchida (1929). The first pair of sacral ganglia have mostly taken a triangular shape. In specimen no. 12 the first and second sacral ganglia had fused on each side to produce a club-shaped figure wider cranially and tapering caudally (Figure 19:20).

The size of the ganglia ranged from 3 x 1-1/2 cm. to 6 x 2-1/2 mm. in the spindle-shaped, and the triangular ganglion at the first sacral vertebra was of an equilateral shape 7 mm. each side. The fused first and second sacral ganglia extended for a length of 18 mm., and were 3-1/2 mm. at their wider end. In the coccygeal region the ganglia were seen as far caudally as the third coccygeal vertebra, and were greatly reduced to much less than 1 mm. in length and considerably narrow.

Rami communicantes

A variable number of Rami communicantes were encountered and not all of them were numerically symmetrical in all of the specimens examined, nor were they symmetrical in number on both sides in each specimen.

In specimen no. 4 there was a Ramus communicans for each of the ganglion and the spinal nerves with the exception of

the L₂ which had two Rami communicantes. In all cases, the ganglia were in the middle of the length of the bodies of the vertebrae and the Rami communicantes coursed caudodorsally to join their respective spinal nerves. Some Rami communicantes also coursed dorsocranially (Figure 4).

In specimen no. 11 there was a Ramus communicans to each ganglion on either side. Between lumbar sympathetic ganglia 1 and 2 a Ramus communicans was joined to the L₁ spinal nerve. A Ramus communicans on both sides of the body, ran dorso-cranially from the cranial end of the L₃ sympathetic ganglion to the L₂ spinal nerve. In this arrangement, therefore, the L₃ sympathetic ganglion was connected with the L₂ and L₃ spinal nerves. Thus, in this specimen much symmetry on both sides of the body was encountered in the arrangement of the Rami communicantes.

In specimen no. 12, however, a different arrangement was presented. This was much different from the foregoing, as well as being different on the two sides of the body. Considering the left side first, the L₁ spinal nerve was connected with the corresponding sympathetic ganglion by three Rami communicantes (Figure 19). The L₂ spinal nerve had two Rami communicantes; the L₃ - L₅ had each a single Ramus communicans but the L₆ had two Rami communicantes. The right side of the body, presented two Rami communicantes for each of the L₁ - L₃ spinal nerves, relative to their respective sympathetic ganglia. The rest of the lumbar ganglia sent

single Rami communicantes to their respective spinal nerves.

In this specimen, too, a contra-lateral Ramus communicans was noted, which extends from the last lumbar sympathetic ganglion to the first and second fused sacral ganglia on the right side. This communication ran obliquely across the lumbosacral intervertebral disc (Figure 19: 19).

Another important disposition concerning the sympathetic trunks was found in the sacral region. This was the direct innervation of the proximal part of the M. retractor penis. From two ganglia, one on each side of the distal part of the third sacral vertebra, intercalated in a normal way in the sympathetic chain, arose apparently Rami communicantes, one on the right side and two on the left. On tracing them further, they were found to end in the M. retractor penis of their respective sides (Figures 19: 12 and 21: 23). The latter figure is of specimen no. 13 in which this type of innervation to the M. retractor penis was encountered on the right side. A similar innervation was also momentarily seen in specimen no. 11, but continuity was lost while trying to clarify the situation (Plate 1: A is a photograph of the rami on the left side of specimen no. 11).

Figure 21 represents the findings in specimen no. 13. In this specimen some clearing of the sympathetic trunks was extended slightly cranial to include the last two thoracic ganglia and their connections to the spinal nerves. On the left side the last two thoracic ganglia showed two

Rami communicantes each. There was one other Ramus communicans joining the interganglionic cord immediately caudal to the last thoracic ganglion. There was one Ramus communicans for each of the L₁ and L₂ sympathetic ganglia. The L₃ sympathetic ganglion was connected to both L₂ and L₃ spinal nerves as in specimen no. 11. The L₄ and L₅ sympathetic ganglia including all the sacral sympathetic ganglia had single Rami communicantes, but the L₆ ganglion showed two Rami communicantes.

On the right side, the last two thoracic sympathetic ganglia and L₁ through all sacral sympathetic ganglia showed single Rami communicantes. Between the L₁ and L₂ ganglia, however, there was an extra Ramus communicans which was connected to the L₁ spinal nerve. Another Ramus communicans connected to the L₂ spinal nerve was also seen between the L₂ and L₃ sympathetic ganglia. The latter ramus was connected close to the L₃ sympathetic ganglion to produce a somewhat similar arrangement as was observed on the left side (Figure 21).

There was observed, too, a direct sympathetic nerve twig to the M. retractor penis at its proximal attachment as was found in the former specimens. This twig was found on the right side (Figure 21: 23).

In this specimen also nerve filaments were seen arising from the ganglia and entering the wall of the lumbar arteries

on the left side, as the arteries left the aorta.

Ganglion impar

Conflicting opinions have been expressed as to the existence of a ganglion impar in the hog. The present investigations have not as yet revealed such an arrangement suggesting its presence. The general arrangement of the sympathetic trunks including the ganglia shows close similarity to the results obtained by Zintzsch (1964) in the sheep. In the present work on the five specimens examined no close contact between the ganglia of the two sides had been encountered. This does not suggest that ganglion impar does not occur at all but its presence was not demonstrated in this investigation.

Some of the Visceral Arrangements of the Sympathetic Nerves in the Abdominal and Pelvic Cavities

The lumbar splanchnic nerves

The lumbar splanchnic nerves have been observed on three specimens only. Specimen no. 11 revealed the following: On the left side three branches were noted; one parted from the sympathetic trunk between the L₂ and L₃ sympathetic ganglia. It was joined by another branch from the caudal end of the L₃ sympathetic ganglion, and a third branch arose from the sympathetic trunk between the L₃ and L₄ sympathetic ganglia. They joined together and formed part of the aortic plexus

which continued caudally to the caudal mesenteric ganglion (Figure 17: 17 and 18: 3). On the right side two branches were observed: One branch left the sympathetic trunk between the L₂ and L₃ sympathetic ganglia, the other arose from the caudal end of the L₃ sympathetic ganglion and continued as part of the aortic plexus on this side, and finally joined the caudal mesenteric ganglion. Both of these aortic plexuses showed a ganglion at the origin of the A. testicularis on each side; and from here each artery had an accompanying sympathetic nerve (Figure 17: 17; 25; and 18: 4, 5, and 6).

The caudal mesenteric ganglia had a meshed exchange of fibers although represented as a simple ganglia in the figures. From here well identified nerve fibers followed the two branches of the A. mesenterica caudalis - cranial and caudal (Figures 17: 18, 19; 18: 4, 7; 19: 17).

From the caudal end of the caudal mesenteric ganglia proceeded the two Nn. hypogastrici (Figures 17: 21; 18: 9; and 19: 18). Each N. hypogastricus met with the N. splanchnicus pelvinus of its respective side on the lateral aspect of the rectum, being firmly secured by the retro-genital fold of the peritoneum.

In specimen no. 12 more lumbar splanchnic nerves were found. Starting with the left side, the abdominal aortic plexus showed five communications with the sympathetic trunk and ganglia, and further communication was found in

the sacral region towards the formation of the Nn. hypogastrici. Figure 19 shows these communications. In the first instance, from the L₁ sympathetic ganglion a single branch was seen; from the L₂ ganglion arose one branch and one other was connected to one of the Rami communicantes. Between the L₂ and L₃ sympathetic ganglia there was one branch; and from the L₃ sympathetic ganglion arose one branch and another one connected to a Ramus communicans. All of these joined the aortic plexus as it passed on caudally to the genital and caudal mesenteric ganglia (Figure 19: 13, 15 and 16).

On the right side, however, only single branches were observed coming off from the first three lumbar sympathetic ganglia. From the last lumbar sympathetic ganglion two branches arose, one of them being the contra-lateral connection to the first sacral ganglion on the left side as was mentioned before; the other one joined the N. hypogastricus of the same side (Figure 19: 19).

In the sacral region, on the left side, two connections were seen leaving the first two fused sacral sympathetic ganglia to join the Nn. hypogastricus of the left side.

Specimen no. 13 showed the following formations of the lumbar sympathetic splanchnic nerves: On the left side, there was a branch arising from the interganglionic cord of the sympathetic trunk which coursed caudomedially, passing

cranial to the origin of the Aa. renalis and phrenico-abdominalis to join the autonomic nerve trunk which ran from the cranial mesenteric sympathetic ganglion and plexus. The lumbar splanchnic nerve here seemed to be a continuation of one of the Rami communicantes connected with the L₁ spinal nerve and sympathetic ganglion. From the L₂ sympathetic ganglion arose one branch. This was joined by another one from the L₃ sympathetic ganglion, and the bundle so formed joined the aortic splanchnic cord or plexus, as it has been so referred to previously. A branch arose from the L₂ spinal nerve and the L₃ sympathetic ganglion. These were joined by another one from the interganglionic cord between the L₃ and L₄ ganglia; and the latter combination was joined by two branches connected with the L₃ spinal nerve, and the resulting bundle then joined that trunk running along the aorta just between the genital ganglion and the caudal mesenteric ganglion.

On the right side, quite a different arrangement was observed. There was no apparent splanchnic connection with the L₁ sympathetic ganglion. Instead, the apparently lesser splanchnic nerve took off from the last thoracic sympathetic ganglion, divided into two branches cranial to the A. phrenico-abdominalis, one branch passing ventral and the other dorsal in relation to the artery. The branch ventral to the artery joined the autonomic nerve trunk from the coeliaco-mesenteric ganglion and plexus. The other branch dorsal to the A. phrenico-abdominalis, continued caudal to the artery,

divided again into two branches one of which also joined the said autonomic trunk running along the aorta, and the other bent laterally and accompanied the right A. renalis (Figure 21: 18).

From the L₂ sympathetic ganglion a splanchnic branch left to join that trunk along the aorta. From the L₃ sympathetic ganglion arose a branch to the aortic autonomic trunk or plexus. Again, from the L₃ spinal nerve came a splanchnic nerve fiber which was joined by another one from the inter-ganglionic cord between the L₃ and L₄ sympathetic ganglia, which subsequently joined the aortic plexus at the spot where the N. genitalis originated to accompany the respective artery.

Pelvic visceral innervation

It is already known that the visceral organs in the pelvic cavity are innervated by both voluntary and autonomic nerves; but the mode under which this is accomplished in the domestic pig is still a matter of conjecture. The present study is most likely to throw light on how the various nerves concerned are distributed to these organs. Observations so far indicate that the Nn. hypogastrici, the Nn. splanchnici and the Nn. pudendi are the ones mainly concerned, but one also has to include the fourth sacral spinal nerve which, when it has not contributed to the formation of the N. pudendus, serves to innervate the most caudal parts of these organs.

Nn. hypogastricus and splanchnicus pelvinus

These nerves were observed to come together to produce the pelvic plexus (Figures 18: 9, 11; 2: 21, 22). It was also noted that a branch from the N. pudendus came cranially alongside the M. urethralis and joined the two nerves at the plexus (Figures 18: 16; 2: 20). From this arrangement nerves passed to the M. urethralis, the bulbourethral gland, the prostate gland, and the seminal vesicle, urinary bladder, and one nerve branch was seen running alongside of the ductus deferens into the inguinal canal (Figure 18: 21). Fibers were traced caudally to the middle part of the M. retractor penis and terminal portion of the rectum (Figure 18: 14).

Origin of the N. hypogastricus

The immediate origin of the N. hypogastricus is the caudal mesenteric ganglion and the plexus formed at this point. It is likely that fibers from ganglia as far cranial as the last thoracic may find their way to this nerve via the aortic plexus, or through the lumbar splanchnic nerves. It is at the caudal mesenteric plexus that fibers were recognizable to be crossing from one side to the other. In one case, however, i.e., specimen no. 12, (Figure 19: 19), and at S₁, some more contributions to the Nn. hypogastrici were seen to come from the L₆ and S₁ sympathetic ganglia, where also contralateral communication between these ganglia was found. From the S₁ sympathetic ganglion on the left side

side arose two splanchnic rami which joined the N. hypogastricus of that side; while from the L₆ sympathetic ganglion on the right side, one splanchnic ramus was observed to join the respective N. hypogastricus.

Origin of the N. splanchnicus pelvinus

Most of the specimens so far examined have had the Nn. splanchnici pelvini originating from the ventral branches of the S₂ and S₃ spinal nerves; i.e, 10 specimens out of 13 showed this arrangement. In the remaining 3 specimens the Nn. splanchnici pelvini were formed by roots from the ventral branches of the S₁ and S₂ spinal nerves.

The N. splanchnicus pelvinus courses ventrally and slightly cranially on the medial surface of the M. obturator internus outside the parietal peritoneum to gain the rectovesical fold of peritoneum, where it meets the N. hypogastricus with which it forms the pelvic plexus. At this point also is found the A. urogenitalis whose branches are intermingled and distributed together with the nerve filaments arising from the pelvic plexus.

Relationship of Nn. pudendus, hypogastricus and splanchnicus pelvinus

As had been mentioned before, the Nn. pudendus, hypogastricus and splanchnicus pelvinus have a reciprocal relationship in supplying innervation to the pelvic viscera.

The N. pelvinus is principally parasympathetic, the N. hypogastricus sympathetic and the N. pudendus mainly voluntary. Electrophysiological methods should be used to determine whether the N. pudendus carries some parasympathetic as well as sympathetic fibers. In all of the specimens examined, the N. pudendus had an unique relationship with the N. splanchnicus pelvinus in that the origin of the former always shared roots with the latter. It was also noted that the Rami communicantes to the roots concerned in giving rise to the two nerves, appeared to be joining the roots which formed the N. pudendus.

The N. pudendus in all cases has had a communicating branch from the N. ischiadicus which joined it at the lesser sciatic foramen. After this communication the combined trunk separated into various branches one of which is of immediate concern here. This branch as shown in Figure 18: 16 and 2: 20, ran alongside the uro-genital organs in the pelvis and was seen to intermingle with the pelvic plexus as formed by both the Nn. hypogastricus and splanchnicus pelvinus. It branched to supply the M. urethralis up to the neck of the bladder and the genital organs up to the cranial end of the vagina. This seems to account for the voluntary innervation in this part of the uro-genital system.

As the various branches of the N. pudendus are followed, quite a number are seen to go to structures in the neighborhood of those innervated by nerve branches from the pelvic plexus as formed by both the Nn. hypogastricus and splan-

chnicus pelvinus. It branched to supply the M. urethralis up to the neck of the bladder and the genital organs up to the cranial end of the vagina. This seems to account for the voluntary innervation in this part of the uro-genital system.

As the various branches of the N. pudendus are followed, quite a number are seen to go to structures in the neighborhood of those innervated by nerve branches from the pelvic plexus. Branches of the N. pudendus go to the M. sphincter ani externus, whereas the pelvic plexus sends branches to the M. sphincter ani internus. The M. retractor penis has been innervated in its distal part by the N. pudendus (Figure 18: 20) and by both the Nn. hypogastricus and splanchnicus pelvinus in its middle part; and in some cases direct sympathetic splanchnics arising from one of the ganglia of the sympathetic trunk, as this crosses the proximal attachment of the muscle (Figures 19: 12 and 21: 23). This latter finding was confirmed by sections made from the nerve filaments shown in microscopic examination which revealed the nerve fibers (Plate 10).

The sympathetic trunks (specimen no. 14) (Figure 22 and Plate 12)

The sympathetic trunk on the right side had two remaining lumbar sympathetic ganglia situated in the middle of the

length of the bodies of the last two lumbar vertebrae as was noted in the previous specimens. In addition, there was an extra ganglion placed onto the intervertebral disc between the last lumbar vertebra and the sacrum, and it was named the Ganglion paravertebrale assessorius. It was intercalated in a collateral sympathetic cord which was given off at the caudal end of the last lumbar sympathetic ganglion. This extra ganglion then gave rise to two nerve cords one of which passed laterally and joined the first sacral sympathetic ganglion, the other had already been severed, but it might have been joined to the N. hypogastricus of the same side as was the case in specimen no. 12; or it might have crossed to the opposite side as also was found in the same specimen. But the last assumption was proved not to be so because the sympathetic trunk on the opposite side was quite intact in the region where the contralateral communication might have joined it.

On the left side there was only one lumbar sympathetic ganglion remaining as was mentioned before.

The sacral sympathetic ganglia were all well represented and the following features were noted. The first pair, which in most cases was triangular in shape its right side ganglion took on a quadrangular shape because of the four cords that were attached to it; two cranially and two caudally (Figure 22: S₁).

The second pair of the sacral ganglia were joined by a transverse anastomosis from which the A. sacralis mediana received filaments.

The third pair also was communicating in a plexiform manner, the left ganglion appearing more caudally placed than the right one. The cord of the left side split into three branches two of which joined the respective ganglion, and one crossed to the opposite ganglion. From the ganglion on the right side an oblique ramus joined the ganglion on the left side (Figure 22: 12).

The fourth sacral and the two conspicuous coccygeal ganglia were closely applied to the A. coccygea mediana. Small filaments were seen to be joining the artery in this region caudally. After the fourth coccygeal vertebra the sympathetic trunks became very tiny and difficult to isolate, but they showed themselves to be fusing at one point and separating at another to allow passage to blood vessels going to the dorsal aspect of the tail.

The findings in specimen no. 14 stimulated more interest to check on another female specimen with the hope of finding some similar arrangements of the Tr. sympatheci in the lumbosacral region. Fortunately enough this turned out to be the case. The specimen was the fifteenth as already stated before. It was a gilt about eight months old and 120 pounds body weight. The specimen was embalmed and dissection com-

menced one day after embalming. The stomach, intestines (except rectum), spleen, liver and pancreas were removed through a longitudinal incision made along the ventral midline from the pubis to the xiphoid cartilage. The kidneys, genitalia, rectum and the aorta were left in position. Dissection to expose the Tr. sympathici was carried out by gentle removal of the parietal peritoneum along the lateral borders of the sublumbar muscles, reflecting it toward the medial aspect of the muscles, locating the various sympathetic nerve rami and splanchnic nerves as far forward as the last three ribs. It was necessary also to remove the costal parts of the diaphragm up to the level of the aortic hiatus, but leaving the crura of the diaphragm intact as the last thoracic splanchnic nerves traversed their lateral surfaces (Figure 23).

The ganglia

In the exposed thoracolumbar part of the right side, three thoracic and six lumbar sympathetic ganglia were seen along the main sympathetic trunk. Both these and those on the left side appeared to be poorly formed, as their boundaries were not clearly demarcated.

On the left side, too, three thoracic ganglia were exposed, and there were six lumbar sympathetic ganglia placed similar to those on the right side, and an extra one in the course of the Nn. splanchnici lumbales (Figure 23: 2).

The coelico-mesenteric ganglia

The coeliac and mesenteric ganglia formed two thick portions which were quite well interconnected by several bands in a form of network. The portion on the right side was situated more caudal than the left portion. It was more quadrangular in outline. That on the left side was of a narrow triangular shape whose apex was directed caudally. It extended cranially to the left lateral aspect of the A. coeliaca. Each of these portions was covered ventrally by the respective adrenal gland (Figure 23: 4). From these ganglia on the left side, were seen strands which joined up to form the renal plexus by joining first with one of the Nn. splanchnici lumbales (Figure 23: 3). After meshing caudal to the ganglia and then joining the renal ganglion. Figure 23: 6 shows the renal plexus on the right side represented by two strands, and had no visible renal ganglion.

There was a well developed and separate Ganglion renale on the left side (Figure 23: 5).

The genital and caudal mesenteric ganglia

In two of the previous specimens examined the genital and the caudal mesenteric ganglia were separate. In this specimen, however, the two ganglia were combined at the site of origin of the A. mesenterica caudalis, from where also the two Aa. utero-ovaricae took origin. No definite indication as to their having joined was observed, but it was an

assumption taken as a result of the arrangement of the nerves originating from here to the parts of the genitalia which had a separate ganglion in the previous specimens. In other words, it may be said that in this particular specimen the caudal mesenteric ganglion served all the organs as shown in Figure 23: 7, 8, 9, and that there was no genital ganglion. The fact that separate vessels to the genitalia arose from the same spot as the A. mesenterica caudalis, may be an influencing factor to support the assumption that the genital and the caudal mesenteric ganglia had joined (Figure 23: 7, H and J; 25: 1).

Ganglia in the sacral and coccygeal regions

Four pairs of sacral sympathetic ganglia were seen. The first two ganglia on each side were well developed and triangular in outline, but the last two were rather small. All of them were evenly placed in the middle of the vertebral bodies (Figure 24: 1, 2).

The coccygeal sympathetic ganglia appeared to fluctuate in size, some being imperceptibly small and others just large enough to identify. Three pairs and one single ganglia were found, all lying in the middle of the vertebral bodies, along the A. coccygea mediana up to the fourth coccygeal vertebra where the single ganglion was found. The two sympathetic cords converged to this ganglion so that it took

a position dorsal to the artery. It seems this may be the pattern in the female pig. Botár (1932) shows a similar finding (Figure 24: at Cy₄).

The interganglionic sympathetic cords

The interganglionic cord on the right side, as seen at the level of the last three thoracic vertebra, was thick. Almost all of it formed the two last thoracic splanchnic nerves which joined the adrenal plexus as well as the coeliaco-mesenteric ganglion and plexus. A small cord, however, continued to the last thoracic sympathetic ganglion from which the last thoracic splanchnic nerve arose to join the caudal part of the coeliaco-mesenteric ganglion. From the last thoracic sympathetic ganglion to the second sacral sympathetic ganglion, the interganglionic cord maintained an even size. After the second sacral ganglion the cord diminished considerably, until it joined the single ganglion which it shared with the cord of the opposite side at the middle of the fourth coccygeal vertebra (Figure 24: Cy₄).

On the left side, also starting with the last three thoracic vertebrae, the interganglionic sympathetic cord was a very small strand lateral to the cranial part of the last three thoracic splanchnic nerves. It, however, fused with the splanchnic nerves at the last thoracic vertebra before the splanchnic nerves parted from it to join the coeliaco-mesenteric ganglion and the adrenal plexus. From here it

maintained a fairly even size, slightly bigger than the cord on the right side, down to the second sacral sympathetic ganglion. Although at this point it began to diminish in size, it was still proportionately larger than the cord on the right side.

As mentioned before, the two interganglionic cords, right and left, joined at a coccygeal ganglion placed at the middle of the body of the fourth coccygeal vertebra. From here they irregularly branched and reunited, forming loops around the vertebral arterial branches from the A. coccygea mediana, and at the same time enlacing the main artery as shown in Figure 24: 1 and 2.

Transverse communications were seen at the first, second and third coccygeal sympathetic ganglia also (Figure 24: 2).

The Rami communicantes

Right side The cranial ganglion of the last three thoracic ganglia exposed had one Ramus communicans each, the next two, although the caudal of these was away from the ganglion and appeared to go direct into the formation of the splanchnic nerve. The last thoracic ganglion had two Rami communicantes one of which was caudal to the ganglion.

The first lumbar spinal nerve was joined by two Rami communicantes one from the first lumbar ganglion and the other from the cranial end of the second lumbar ganglion.

There were two Rami communicantes to the L₂ spinal nerve, one from each of the L₂ and L₃ sympathetic ganglia, but part of the Ramus from the L₃ ganglion appeared to be continued by the second of the Nn. splanchnici lumbales on this side. The L₃, L₄, L₆, the sacral and all of the coccygeal sympathetic ganglia had single Rami communicantes, whereas the L₅ ganglion had two.

Left side The last three thoracic ganglia had arrangement of the Rami communicantes similar to that noted for the Rami of the right side.

All of the sympathetic ganglia except the L₄, in the lumbar region had two Rami communicantes each. It was noted too, that the caudal Rami communicantes between the L₂ and L₃, and the L₃ and L₄ ganglia were either joining the interganglionic cord or appeared to be joining the Nn. splanchnici lumbales.

The sacral and coccygeal ganglia had single Rami communicantes.

The splanchnic nerves

Thoracic The part of the thorax exposed showed two splanchnic nerves on the right side. Both of these nerves appeared doubled as they left the immediate ganglia. From the cranial of them one small N. splanchnicus entered the cranial third of the adrenal gland, whereas the remainder joined the coeliaco-mesenteric ganglion. From the coeliaco-

mesenteric ganglion, four twigs were observed to enter the caudal half of the adrenal gland (Figure 23: at 2).

On the left side, the thoracic splanchnic nerves appeared to be six in number as they left the sympathetic cord. Three of them were large and three small ones. The cranial two small ones and one large entered the adrenal gland, while the caudal two large ones joined the tapering caudal end of the coeliaco-mesenteric ganglion; and the most caudal and small N. splanchnicus divided towards its termination, one branch joining the ganglion and the other branch joining one of the branches of the A. adrenalis which came from the A. renalis by a common trunk with the A. phrenico-abdominalis. Four twigs were seen passing between the adrenal gland and the coeliaco-mesenteric ganglion on the left side.

On the right side, two nerves sprang from the coeliaco-mesenteric ganglion and ran along the A. renalis as the renal plexus (Figure 23: 6).

On the left side, from the tapered part of the coeliaco-mesenteric ganglion, a thick cord extended to a separate ganglion -- the renal ganglion -- from which four filaments arose. One of these filaments followed the A. renalis, one the A. phrenico-abdominalis, and two crossed over the ventral and dorsal aspects of the A. renalis and joined the Nn. splanchnici lumbales (Figure 23: 3, 5, 6).

Lumbar There were three Nn. splanchnici lumbales on

the right side. The first N. splanchnicus lumbalis joined the caudal part of the coeliaco-mesenteric ganglion on the same side. The second N. splanchnicus lumbalis parted with the sympathetic cord between the L₂ and L₃ sympathetic ganglia, while the third N. splanchnicus lumbalis appeared to spring from the cranial end of the L₃ sympathetic ganglion and partly as a ramus communicans to the L₂ spinal nerve. The L₂ and L₃ splanchnic nerves joined together at the level of the fifth lumbar vertebra, and the resulting trunk joined the caudal mesenteric ganglion, which, as described before had fused with the genital ganglion (Figure 23: 3 and 7).

On the left side there were about five Nn. splanchnici lumbales which appeared to have taken origin from one spot between the L₂ and L₃ sympathetic ganglia, and one N. splanchnicus lumbalis was from between the L₃ and L₄ ganglia. They all joined up at the level of the fifth lumbar vertebra then separated into two cords which joined the cranial wide part of the caudal mesenteric ganglion on the same side (Figure 23: 7, cranial end).

Sacral and coccygeal regions

The caudal mesenteric ganglion gave rise to a number of nerves. This statement does not imply that the nerves solely started from here, as it is understood many of their fibers may have passed without synapsing at all. From this ganglion arose the N. hypogastricus, as well as nerves which followed

the two branches of the A. mesenterica caudalis, and nerves to the genitalia -- ovary and uterus.

N. hypogastricus This nerve left the caudal end of the ganglion in a similar manner on the two sides of the body, coursed horizontally alongside the rectum, and turning somewhat ventrally and caudally in the cranial third of the pelvic cavity, came in contact with the N. splanchnicus pelvinus with which it formed the pelvic plexus at the neck of the urinary bladder and cervix uteri (Figure 25: 2,3). Along with the nerve was the A. urethrogenitalis (Nunez, 1964) or A. urogenitalis (Getty, 1964) which vessel is distributed together with the various filaments of the pelvic plexus (Figure 25: M). A well isolated nerve was seen following the rectogenital branch of the A. urethrogenitalis towards the anus. To the same point, i.e., at the place where the N. hypogastricus and N. splanchnicus pelvinus joined, came a branch from the N. pudendus which also took part in the plexus production, as was found in the male pig (Figure 25: 2, 3, 4, and 9).

Nerve plexus to A. colica sinister and A. hemorrhoidalis

At least three filaments were seen proceeding from the caudal mesenteric ganglion on the left side following the arterial branches of the A. mesenteric caudalis. They arose from the medial aspect of the ganglion, cranial, middle and caudal in relation to the main body of the ganglion. The

cranial and caudal components appeared to be formed by fibers from the right and left ganglia, while the medial component sprang directly from the ganglion. Two of the filaments accompanied the A. colica sinistra and the third followed the A. hemorrhoidalis. In specimen no. 12 another nerve arose together with the N. hypogastricus on either side, and these converged to follow the A. hemorrhoidalis a short distance from the bifurcation of the A. mesenterica caudalis (Figure 23: 10, 11, H).

Nerve plexus to the genitalis

In specimen no. 15 the nerves contributing to this plexus arose from the amalgamated genito-mesenteric ganglion. These nerves separated from the ventromedial aspect of each ganglion and descended together with the A. utero-ovarica. As these nerves gained the meso-ovarium they divided after the manner of the vessels, but their final branches were not easily traceable. A ureteral nerve was observed to come from the same point and followed the A. ureteralis to the ureter. The relationship of the N. hypogastricus and N. splanchnicus pelvinus was much the same as that found in specimens no. 11 and 12 (Figure 25: 2, 3 and 6 shows the nature of their arrangement into the pelvic plexus). The nerve pudendus also anastomosed with the N. hypogastricus and N. splanchnicus pelvinus. From here some filaments were traceable to the bladder, vagina and caudal part of

the uterus. A considerably large strand runs from the meeting point of the three components of the plexus, in company with a recto-anal branch of the A. urethro-genitalis, to reach the M. sphincter ani internus (Figure 25: 5).

DISCUSSION

The Somatic Nerves

The somatic nerves in the lumbar and pelvic regions

The number of the lumbar vertebrae determines the number of the lumbar spinal nerves present. In the present investigation all specimens, except two, had six lumbar vertebrae. In the two exceptions one had five lumbar vertebrae as a result of the presence of an extra pair of ribs, the other specimen was not examined fully to count the number of the lumbar vertebrae and only its sacro-coccygeal part was salvaged for studying the caudal termination of the Truncus sympatheci.

All of the textbooks consulted (Ellenberger and Baum, 1943; Martin, 1923; Montané and Bourdelle, 1920) agree that there are usually seven lumbar vertebrae, or sometimes six in the pig, and consequently the corresponding number of nerves. The present investigator, however, found in his specimens that there were six lumbar vertebrae in most of the cases, 13 out of 14 (this excludes the one specimen whose lumbar vertebrae were not examined). One out of fourteen specimens had only five lumbar vertebrae. The work of Reimers (1913) confirms the presence of generally seven lumbar vertebrae with a reduction to six. Uchida (1929) found six pairs of lumbar sympathetic ganglia in all the specimens

he examined. These, in the opinion of the present investigator, were equated with the lumbar vertebrae present.

Horses, cattle, goats, and sheep each have six lumbar vertebrae, but the dog, cat and rabbit mostly have seven, although in the cat and rabbit the reduction to six lumbar vertebrae is more likely than it is in the case of the dog.

After encountering an extra pair of ribs in one specimen, it was deemed proper to find out whether or not the varying numbers of ribs had any influence on the number of the lumbar vertebrae. However, this was not so because in those animals which had fifteen or sixteen pairs of ribs, the number of lumbar vertebrae still was six.

Intercommunication between the ventral branches of the lumbar spinal nerves

As indicated before, the intercommunication between the ventral branches of the Nn. spinales lumbales made it possible to say that all spinal nerves in the lumbar region play a part in forming the lumbosacral plexis. It is worthwhile reporting how they do so.

In specimen no 4 (Figure 4: Th and L) a communication was observed on the left side between the last thoracic spinal nerve and the ventral branch of the L₁ spinal nerve before they subdivided. It is the only case in which this communication was observed, probably because the number of the lumbar nerves had been reduced.

In specimens no. 2, 3, 4, 11, 12 (Figures 1, 3, 4, 18 and 19, respectively) a communication between the ventral branches of the L_1 and L_2 spinal nerves occurred. This seems to disagree with the findings of Reimers (1913) whose specimens did not reveal this communication between the first two ventral branches of the lumbar spinal nerves, notwithstanding the fact that his specimens had seven lumbar spinal nerves excepting one case in which six lumbar spinal nerves occurred.

The distance from the intervertebral foramen at which this communication takes place varies from animal to animal and also in the same specimen on the two sides of the body. In some cases this communication takes place near the nerve exit from the vertebral canal as shown (Figure 19) on the right side of specimen 12, or the communication may be several cm. away, as shown in the same specimen on the left side (Figure 19); still in other cases communication occurs at the point where the various branches begin to subdivide, this form of communication being the most common and involving all of the ventral branches of the lumbar spinal nerves from and including the L_2 spinal nerve.

Specimens were encountered in which the communicating branches joined, not only their immediate neighbors, but coursed to succeeding branches. This is exemplified in the ventral branches of the L_3 spinal nerve, in which fibers

could be traced from the L₃ across the L₄ and L₅ to continue in the N. obturatorius, at the same time receiving contributory fibers from the nerves crossed over.

It is this type of communication which led the investigator to include the ventral branches of the last four lumbar spinal nerves in the formation of the lumbosacral plexus.

The nerves to the sublumbar muscles

The sublumbar muscles which comprise the Mm. psoas major, minor and quadratus lumborum iliacus are innervated by muscular branches from the L₁ through the L₆ (or to the last lumbar spinal nerves, as there is a variation in this number).

While the first two and last two lumbar spinal nerves do give well isolated muscular branches to these muscles, the nerves in the middle section of the series, particularly the L₃ and L₄ spinal nerves, tend to produce a secondary plexus which innervates the Mm. psoas major and minor (Figure 13: between the L₃ and L₄). The ventral branch of the L₃ spinal nerve, in all of the specimens, gave off a stout branch which ran cranially into the substance of the M. psoas major as far as its cranial attachment. As was mentioned in the findings, one similar branch traveled cranially through the muscle of one side and joined with another branch from the L₂ inside the muscle; the conjoined

nerve branch penetrated the ventral surface of the M. psoas major and turned caudally to terminate in the M. obliquus internus abdominis. This occurred in specimen no. 6 (Figures 7: 6 and 8: 6). The joining of the L₂ and L₃ spinal nerves was common in all specimens, except specimen no. 4 in which it occurred between the L₁ and L₂ spinal nerves (Figures 1: 7; 4: 1, 2; 21:). In some cases again the conjoined branch innervated the M. cremaster externus, (Figures 19: 3; 21: 3) taking an independent course from that of the N. genitalis (N. spermaticus externus). The nerve arrangement for the M. psoas major is shown in Figures 1: 8; 3; 4; 5: 3a, 8; 17: 3; 21: 4.

The ventral branches of the L₅ and L₆ spinal nerves give off numerous branches which innervate the M. iliacus, and come off more or less from the N. femoralis.

The somatic nerves in the lumbar region should be related to the function of the animal's parts innervated by those nerves. The first four Nn. spinales lumbales together with the last thoracic spinal nerve, as considered in this work, innervate the abdominal wall. The formation of the plexus and the continuation of some of their fibers into the pelvic cavity and hind limb is in a metameric manner, where a nerve in the cranial part has an overlapping area of distribution in which the succeeding nerve takes part thus causing a wave of movement starting in the cranial

portion of the body carried on harmoniously to the caudal portion. Table 1 shows the arrangements of these nerves.

The numbers of the nerves as given in this table are a result of macroscopic observations on teased nerves. Some could be followed on but others, although formed in a similar way, were too delicate for much teasing and follow up, so that some doubt will still exist until physiological electrical stimulation is performed to confirm or verify the morphological findings.

Further consideration is given to such nerves as the N. genitalis (N. spermaticus externus) and N. obturatorius. The choice of the name N. genitalis as against N. spermaticus externus was initiated by the fact that it can be used on both sexes. As was noted in the findings, it came mostly from the ventral branch of the L₃ spinal nerve with a contribution from the ventral branch of the L₄ spinal nerve, and in a few cases the N. genitalis was formed mainly by the ventral branch of the L₂ spinal nerve and a contribution from the ventral branch of the L₃ spinal nerve.

Although Reimers (1913) points out the singleness of this nerve in the pig as compared to two in cattle, cases were encountered where the branch which forms the second nerve in cattle, was the one running separately from the ventral branches of the L₂ and L₃ spinal nerves which terminated in the M. cremaster externus (Figures 5: 4a; 19: 3; 20: 12; 22: 3). However, the main nerve in all cases separates after

the exchange of fibers with the N. cutaneus femoris lateralis. Thus the N. genitalis enters the inguinal canal by two branches which then constitute the N. inguinalis which continues to the inguinal region in both the male and female.

Reimers (1913) noted that the N. obturatorius received an inconstant, reinforcing slender branch from the L₇ spinal nerve, and apparently continuing fibers from the L₅ spinal. The difference here then is the presence of seven pairs of lumbar nerves in Reimer's specimens, otherwise his finding agrees closely with the present investigation.

The sacral somatic nerves

The sacral somatic nerves arise from the caudal part of the lumbosacral plexus. These nerves have already been considered under results, but further explanation is given here. The ventral branches of the N. spinales lumbales which cross over to the sacral region and join with the ventral branches of the N. spinales sacrales are responsible for the formation of the lumbosacral plexus. While most of the nerves emanating from this part of the plexus are fairly distinct a few of them tend to be confusing.

The N. glutaeus cranialis tends to split up immediately on leaving the plexus at the craniolateral border of the greater sciatic foramen. In some cases it consists of widely separated twigs radiating from the sciatic foramen. Reimers (1913) also noted the shortness of this nerve and its

immediate dividing. The nerve to the *M. gluteus profundus* runs caudally in a horizontal manner on the surface of the muscle and in many cases appears to be an independent nerve branch of the *N. ischiadicus* lying in series with the branches which leave the latter nerve to supply the *M. gemellus*. Reimers points out muscular branches to the *Mm. gemelli* and *M. obturator externus* to be given off from the ischiatic plexus or later from the *N. ischiadicus*.

The *N. ischiadicus* is the most well formed member in the sacral region of the lumbosacral plexus. It appears as a wide flat band lying upon the *M. gluteus profundus*, *gemellus* and *quadratus femoris* as it turns at the hip joint to descend into the thigh. Its full course is described under results. However, it is worthy of mention that there is a very constant communicating branch between the *N. ischiadicus* and the *N. pudendus*. In most cases after this branch has joined the *N. pudendus* the branches resulting from a conjoined trunk shared the fibers of the two, thus, for instance, the continuation of the *N. pudendus* as the *N. clitoridis* or *N. dorsalis penis* and the *N. mammarius* or *N. scrotalis medius* shared the fibers which came from the roots of the *N. pudendus* as well as those which came via the communicating branch from the *N. ischiadicus*. There were nevertheless twigs which split from the communicating branch which passed on without joining the *N. pudendus*. These, apart from being part of the *N. gluteus caudalis* were

included in the N. cutaneus femoris caudalis (Figures 2: 8, 10, 16, 17; 3: 13, 19, 20, 21, 22; 5: 15, 19, 24, 26, 27; and 10: 1, 3, 5, 6, 7, 8).

Reimers (1913) shows the communicating branch heretofore referred to as the N. cutaneus femoris caudalis. Fibers from it, at times together with some from the N. pudendus and sometimes fibers from the N. glutaeus caudalis, form the representative of the N. cutaneus femoris caudalis.

Larson and Kitchell (1958) working on bull calves and rams indicated that the nerve branch proceeding from the N. ischiadicus to the N. pudendus joined the N. perinealis and no fibers passed to the N. pudendus. Thus, apparently there is a difference between species since the arrangement in the pig was different.

The N. pudendus, as was described before, has as its main root the ventral branch of the S₃ spinal nerve and the S₂ spinal nerve, while the S₁ and S₄ spinal nerves take part on rarer occasions. The most important point to realize about the N. pudendus is the role it plays in innervating many and variable structures, especially those of the reproductive intrapelvic and extrapelvic parts. In the intrapelvic part it sends a branch cranially which innervates the striated muscles of the urogenital tract, and, has appeared to reach, and be distributed with, branches of the pelvic plexus (Figures 2: 20; 5: 20). The other branches given off

by the N. pudendus are: a muscular branch to the M. coccygeus and the N. cutaneus femoris caudalis has arisen most commonly with the N. pudendus, although it may not at all times first join it and then separate from it before dipping into the lesser sciatic foramen. Here also should be mentioned the Nn. perineales profunda which represent numerous branches arising sometimes independently, or together with the N. perinealis superficiales, at the lesser sciatic foramen (Figures 2: 11, 12, 15, 16, 17; 3: 13, 15, 18, 21; 5: 24, 27, 28).

The N. pudendus continues ventrally to the ischial arch where it divides into its terminal branches, in the male the N. dorsalis penis and N. scrotalis medius, or in the female, the N. clitoridis and N. mammarius. While in the male the N. dorsalis penis is the longer, in the female it is the N. mammarius which is longer.

The N. perinealis superficialis has been termed the N. labialis in the female, and the N. scrotalis caudalis in the male; the continuing branch to the mammary glands has been termed the N. mammarius caudalis, the corresponding nerve in the male is the N. scrotalis medius. The latter two nerves are arborized in the septum scroti.

N. cutaneus femoris caudalis

The N. cutaneus femoris caudalis varies much in its origin and course. It has been described, and given as its

origin the ventral branches of the S₁, S₂ and S₃ spinal nerves, with the S₂ spinal nerve being the most frequent and the S₁ spinal nerve the least frequent. In most cases it consisted of several strands, one of which coursed in the texture of the sacrospinotuberal ligament for some time before lying between the proximal parts of the Mm. biceps femoris and semitendinosus. Other strands run in one bundle with the N. pudendus and part with it as it gains the gluteal surface of the sacrospinotuberal ligament. Frequently, the strands forming the N. cutaneus femoris caudalis spring by the exits of the ventral branches of the S₁ and S₂, and S₂ and S₃ spinal nerves and join together immediately at, or after, crossing the S₃ spinal nerve by running through the ligament and arriving at their destination (Figures 2: 12; 3: 13; 5: 23; 13: 12; 15: 4). In some cases in which only the ventral branch of the S₂ spinal nerve constitutes the N. cutaneus femoris caudalis, the latter runs independent of the N. pudendus (Figures 10: 4; 11: 4).

It was noted in connection with the N. glutæus caudalis that some fibers running together with it were to be regarded as part of the N. cutaneus femoris caudalis as they innervated the same area. However, this need not be considered as a criterion for determining any particular nerve, for the basically termed muscular nerves also have some cutaneous nerve branches associated with them.

The Nn. perineales

These nerves exist as branches of the N. pudendus, and are easily confused with the N. cutaneus femoris caudalis at the point where they branch off from the parent nerve. They consist of superficial and deep sets whose numbers are undefined. They may arise in succession or as single stems which separate during their course near their origin or later near their terminations. The ones which innervate the skin of the perineum are included in the superficial set and those which end in the striated musculature of this region are the deep set (Figures 2: 15, 16, 17; 3: 18, 21; 5: 27, 28; 10: 7, 8; 12: 16, 17; 18: 15).

The Nn. perineals superficiales begin as a common trunk with the Nn. perineales profundi, which separate soon or late and run near the tuber ischii, and penetrate the tuberos attachment of the sacrospinotuberal ligament after which they divide. One or more branches pass medially to the skin around the anus and upper part of the vulva; the other, usually larger branch continues over the ischial end of the M. semimembranosus, and supplies branches to the skin here as well as that below the vulva in the female, or that of the scrotum on the perineal surface in the male (Figures 2: 15; 3: 18; 5: 27; 10: 8; 12: 17). In the female these nerves have been termed the Nn. labiales caudales and in the male, Nn. scrotales caudales. Further branches which did not travel the way described separated from branches of the

Nn. perineales profundi and coursed laterally to the anus and upper part of the vulva (Figure 10: 7).

The Nn. perineales profundi after parting with the superficial set, in their initial part course through the ischio-rectal fascia and gain entrance to the Mm. sphincter ani externus and constrictor vulvae in the female, and a homologue of the latter muscle of the male. They also innervate the M. levator ani in conjunction with the Nn. rectales caudales. As indicated above these nerves are not completely restricted to the muscles, but send cutaneous twigs around their respective areas of innervation (Figures 2: 15; 10: 7). Arising separately from the N. pudendus are the branches which innervate the Mm. ischiacavernosus, sphincter urethrae and bulbourethralis.

N. mammarius caudalis s. N. scrotalis medius

While still discussing the Nn. perinei, it is worthwhile to correlate the behavior of the N. mammarius. This nerve is one of the terminal branches of the N. pudendus given off at the ischial arch. It sends cutaneous branches along its course in the female (Figures 2: 19; 3: 23; 5: 30). Its terminal branches anastomose with the terminal branches of the N. genitalis, which are by this time called the N. inguinalis.

In the male (Figure 13: 13) the N. scrotalis medius also anastomosed with the N. inguinalis, the continuation of the

N. genitalis which gives off a branch that goes towards the scrotum.

This nerve was grouped as the N. perinealis superficialis by Larson and Kitchell (1958) in the bovine and ovine. The argument here was that it does not innervate the skin and therefore should not be termed superficial. As is shown here in the pig this particular nerve innervated the skin as it courses towards its destination to the mammary glands or the scrotum depending on sex. It therefore carried both cutaneous and deep structure fibers.

It must be emphasized here that the mode of disposition of the Nn. perineales, both superficial and deep, is frequently difficult to delineate.

The N. rectalis caudalis

This nerve arises mainly from the ventral branch of the S₄ spinal nerve and in all cases it had either direct or indirect communication with the ventral branches which form the N. pudendus. The N. rectalis caudalis runs caudally under cover of the M. sacrococcygeus ventralis which it leaves near the anal region to innervate the Mm. sphincter ani externus and levator ani and the skin around the anus. Sometimes it runs alone but often a branch from the N. pudendus may join it early or near its termination. The branch from the N. pudendus running alone to the same area tempts one to use the name N. rectalis medius, but as it is

not enlisted in the nomenclature followed, it is less confusing to include it as either the Nn. rectales caudales or Nn. perineales profundi. In the case in which it innervates very closely related structures to the ones innervated by the nerve from the S₄ spinal nerve, it is included in the Nn. rectales caudales (Figures 1: 19; 2: 14; 3: 16; 4: 11; 5: 25; 26; 11: 7; 12: 18, 19; Plate 1: 15).

The end of the spinal cord relative to the origin of the spinal nerves

The vertebral canal was opened and the spinal cord was exposed to obtain a definite idea about the best place where each nerve could be stimulated following laminectomy. Jankovic (1954), as quoted by Goller (1959), found that the first lumbar segment lies in the corresponding number of the vertebra, but the succeeding lumbar segments show a cranial displacement. The lumbar segment ends at the cranial border of the sixth lumbar vertebra, but the intumescentia lumbalis lies between the fourth and sixth lumbar segment. In the present investigation the lumbar segment ended slightly short of the caudal end of the fifth lumbar vertebra. This is fairly in agreement with Jankovic's findings.

In the present investigation the sacral and all the coccygeal segments occupied the part extending from the caudal eighth of the fifth, to the middle of the sixth, lumbar vertebra. In Jankovic's (1954) work, as quoted by Goller

(1959), the Pars sacralis ($S_1 - S_4$) extends from the cranial border of the sixth lumbar vertebra to the cranial third of the second sacral vertebra. The Pars coccygealis lies in the caudal two thirds of the second and third sacral vertebra. This segmentation is obviously quite different from that found in the present investigation. The age of the animal examined has much to do with this variation, for example, in the lamb at birth the spinal cord (conus medullaris) extends to the middle of the fourth sacral vertebra, at two months of age to the middle of the third sacral vertebra, and in full grown sheep to the middle of the first sacral vertebra (Gollar, 1959).

The Autonomic Nerves

The sympathetic trunks (Trunci sympathici)

The sympathetic trunks in the lumbar region are regularly located between the M. psoas minor on the right and left, dorsolateral to the Aorta abdominalis and Vena cava caudalis. They are beset with constant ganglia placed alongside the middle of the body of each vertebra. According to Botár (1932) they are similar to those of the cat and dog except that they have more regular relationships. Dyce (1958) states that they show a tendency to coalescence in the horse, which quality, although seen in a few cases in the sacral region (Figure 18: 20), was not observed in the

lumbar region. There were six pairs of ganglia in most of the specimens except two, one of which had five lumbar vertebrae and the other in which the whole of the lumbar region was not utilized (Figures 4; 17; 18; 21). In one other specimen, however, the ganglia and trunk on the right side were obviously less pronounced than those on the left side (Figure 23). Uchida (1929) had a similar number of pairs of the lumbar sympathetic ganglia. The shape of the ganglia were much more influenced by the Rami communicantes which connected them with the spinal nerves. The general shape is spindle, but when the Rami communicantes are joined to the side a triangular shape results.

An extra ganglion was found at the disc of the lumbosacral junction (Figure 22: 11) and Botár (1932) had named a similar finding the Ganglion paravertebrale accessorium. Although it did not occur in the same position as the one shown in the illustration, this name seems worthy of adopting. In specimen no. 12 (Figure 19: 19) are shown two oblique Rami on the right side. Both of them started at the L₆ sympathetic ganglion and ended by joining the N. hypogastricus; the other ramus continued its oblique direction to the S₁ sympathetic ganglion. From the latter ganglion two splanchnic rami ran mediocaudally and ventrally to join the N. hypogastricus.

In the lumbar region some rami were seen following the

lumbar vessels, but no transverse communication between the two trunks were found. Botár (1932) recorded a number of them, and Zintzsch (1964) shows these to be present at almost every segment in the sheep.

The sympathetic trunks in the sacral region lie closer to the A. sacralis mediana after the second segment of the sacrum and continue in this manner along the A. coccygea mediana. The first pair of the sacral sympathetic ganglia is very outstanding in point of size, and usually has an equilaterally triangular shape. Each lies near the course of the A. iliaca interna. In specimen no. 12, the first and second ganglia fused and produced a club-stick shape, wider cranially and tapering caudally (Figure 19: 20).

There were observed Rami transversi between some of the sacral and coccygeal ganglia starting with the second sacral segment to the fourth coccygeal vertebra, at which point the trunks joined to form a single ganglion in specimen no. 15. The ganglion was slightly on the left side although somewhat dorsal to the A. coccygea mediana (Figure 24: at Cy₄). In specimen no. 14 the S₃ sacral sympathetic ganglia were close together and had strands of nerves meshing between them (Figure 22: 12).

In the part beyond the fourth coccygeal vertebra the two trunks joined and separated again alternately and at the same time detaching oblique rami which passed either dorsal or

ventral from one side to the other, thus enlacing the *A. coccygea mediana*. Two of the specimens, no. 14 and 15, revealed this type of arrangement. In most cases the ganglia were not easily seen and the sympathetic trunk was difficult to pursue beyond the ninth vertebra. Botár (1932) reports that beyond the sixth coccygeal vertebra the trunks disappear near the artery. The specimens, no. 14 and 15, in which this arrangement was observed were both females, and in the illustrations shown by Botar the one for the female has a resemblance to Figure 22 and 24; Plates 12, 13). Frewein (1962) reported that, in the ox, macroscopically visible ganglia and rami transversi occurred in relation to the first four, or five in one case, coccygeal segments, and that at the end of the chain ganglia, a *Ganglion coccygicum impar* is regularly found. He continues to report that from that ganglion a filament goes to form the coccygeal plexus along the *A. coccygea mediana*.

At each vertebral segment fine filaments were given to the *A. sacralis mediana* and the *A. coccygea media*. In specimen no. 14, the first sacral sympathetic ganglion formed a loop surrounding the vessel that was passing into the sacral canal. Their fine nature makes it easy to miss these branches in some specimens, Botár (1932) experienced a similar problem. Still Zintzsch's (1964) illustrations show their common occurrence in the sheep.

The Rami communicantes

These are irregular in the number present on both sides of the body, especially in the lumbar region, where at some segments there are two or three rami and at others only one Ramus communicans is found. In the sacral and coccygeal region single Rami communicantes are constantly found (Figures 4, 17, 19, 21, 22, 23, 24). While most of the Rami communicantes are connected to the ganglia some of them join the trunks between ganglia and in some cases they appear to continue as the Nn. splanchnici (Figures 17, 19, 21, 23; Plates 11, 13, 14a).

The splanchnic nerves (Nn. splanchnici)

The Nn. thoracici splanchnici were observed, appearing at the level of the last two thoracic vertebrae winding lateral to the crura of the M. diaphragma. There were more of these on the left side than on the right (Figures 17, 21, 23; Plates 13, 14a). They joined the G. Coeliacomesentericum and adrenal plexus.

The lumbar splanchnic nerves were observed again to be more on the left than on the right side (Figures 17, 19, 21, 23; Plates 13, 14a). Four to five or more were present on the left side while up to three could be made out on the right side. The first of these partly joins the caudal part of the G. coeliaco-mesentericus or adrenal plexus or it may join the G. renalis. The rest join the intermesenteric

trunks and pass on the ventrolateral aspect of the Aorta abdominalis and end by joining the G. genitalis and G. mesentericus caudalis, but some of them bypass these ganglia and are continued into the Nn. hypogastrici.

The intermesenteric trunks run from the caudal end of the G. coeliaco-mesentericus to the G. mesentericus caudalis and G. genitalis. On their way caudally they receive the Nn. splanchnici lumbales.

The prevertebral ganglia

These comprise the G. coeliaco-mesentericus, G. renalis, G. genitalis, and G. mesentericus caudalis. In the pig these ganglia were all found.

The G. coeliaco-mesentericus as the name indicates results from the fusion of the G. coelicus and G. mesentericus cranialis. They were combined in such a way as to make two masses which were more or less almost fused completely because of the many communicating branches between the two and also between the ganglia and the underlying adrenal glands (Figure 23: 4). The dorsal branch of the N. vagus is also shown (Figure 23: 1). The ganglia surrounds the Aa. coelica and mesenterica cranialis. Dyce (1958) found, in the horse, that the right G. coelicus and G. mesentericus cranialis of the same side join and, in turn, join the opposite side resulting in two masses.

From the fused ganglia run the two intermesenteric trunks.

While a separate *G. renalis* was found on the left side in one of the specimens there was none seen on the right and the renal plexus on the right side started from the caudal end of the *G. coeliaco-mesentericus* of the respective side. The ganglion *renalis* seen on the left side was placed ventral to the origin of the *A. renalis* and was connected with the *G. coelico-mesentericus* and with the first *N. splanchnicus lumbalis*.

The *G. aortico-renalis*, as noted in the horse by Dyce (1958) and in the dog by Miller, Christensen and Evans (1964), was not easily made out in the pig.

The *G. genitalis* was seen separate in three of the specimens examined for this study, and in one specimen it was considered fused with the *G. mesentericus caudalis*. The arteries were also fused at their origin (Figure 23: 7, H, J). The *G. mesenterici caudales* appear fused and lying on either side of the *A. mesenterica caudalis*, with the *A. genitalis* interposed on either side between the former vessel and the gangliar mass. The whole arrangement was plexiform. The ganglia are located at the level of the six lumbar vertebra near the origin of the *A. iliaca externa*. From this ganglion arises the Plexus mesentericus which divides to follow the two branches of the artery, cranially and caudally (Figures 17: 20, 18; 19; 18: 4, 7, 8; 19: 16, 17; 20: 2; 21: 20, 22; 23: 7, 8, 9, 10, 11). Here also arises

the Nn. hypogastrici, which follow the lateral aspect of the rectum and meet with the N. splanchnicus pelvinus at the neck of the urinary bladder to form the Plexus pelvinus.

In one specimen in which the G. genitalis was fused into the G. mesentericus caudalis, the N. genitalis (N. utero-ovarica in this case) arose from here on either side and accompanied the A. utero-ovarica and divided in the manner of the vessel to the ovary, uterine tube and uterine cornu. The ureteral branch arose from the same place and ran cranial along the ureter. Frewein (1962) states that the ureter receives the sympathetic supply from the internal spermatic plexus, Plexus pelvinus, and rarely from the Plexus renalis, this is for the bovine; the latter nerves were not accompanied by vessels.

The Plexus pelvinus N. splanchnici sacrales

The Plexus pelvinus is a bilateral plexus formed by the N. hypogastricus, N. splanchnicus pelvinus and in some cases a contribution from the N. pudendus (Figures 2, 5, 18, 20, 25). It is a plexus responsible for the innervation of the urogenital and terminal digestive tract. The relationship of the three nerve components has been fully described before.

This plexus sends innervation to the bladder, to the ureter, the caudal part of the uterus, the vagina, and the accessory sexual glands. There was also found a branch which followed the ductus deferens which appeared to be continued

from the N. splanchnicus pelvinus (Figures 18: 21; 20: 9; 25: 9). A well established nerve runs from the plexus and continues caudally to the rectum and middle part of the M. retractor penis (Figures 20: 10; 25: 5). While the plexus innervates the smooth muscle organs the N. pudendus innervates those organs having a striated voluntary muscle.

SUMMARY AND CONCLUSIONS

The Somatic Nerves

The somatic and autonomic nerves in the lumbar and pelvic regions of the domestic pig, Sus scrofa domesticus, were studied. This was done by dissections on fifteen specimens consisting of eight females and seven males (four castrated), ranging in age from three months to 6-1/2 years. They were of various breeds: 6 Yorkshire, 3 Poland-China, 2 Landrace, and 4 Yorkshire-Landrace. Lateral and medial approaches were followed to expose the nerves.

The Nn. spinales lumbales consisted of six pairs in thirteen specimens, five pairs in one, and was not counted in one specimen since the cranial part of the lumbar area had previously been removed. The Nn. spinales lumbales showed two modes of arrangement in relation to the Mm. psoas major and minor. In the most commonly encountered mode they leave the intervertebral foramina and pass between the M. quadratus lumborum dorsally and the Mm. psoas major and minor ventrally to emerge from them at their lateral border. The Nn. L₃ and L₄, however, emerged ventrally between the M. psoas major and M. psoas minor, in 13 cases. In one case in which the lumbar vertebrae were five, the Nn. L₂ and L₃ were the ones which emerged between the M. psoas major and M. psoas minor. The ventral branches of the L₂ spinal nerve penetrated the M.

psoas major and emerged from it on the ventral surface of its cranial third in the other mode of arrangement, which was seen in one specimen.

The ventral branches of the L₁, L₂, L₃ and L₄ spinal nerves innervate the paralumbar area of the abdominal wall including the inguinal, caudal preputial, mammary and cranial scrotal areas; the remainder course to the hind limb and the perineum.

All of the ventral branches of the Nn. spinales lumbales have intercommunicating branches between the L₂ and L₆ spinal nerves, inclusively. On occasions connections were seen between the L₁ and L₂ on one side or the other.

The lumbosacral plexus is formed by the ventral branches of the last three Nn. spinales lumbales and the first three Nn. spinales sacrales. In about 46 percent of the cases the fourth component from the lumbar region comprised by the L₃ spinal nerve joined in the formation of the plexus.

The Nn. hypogastricus and ilioinguinalis were present, except in one case in which the former was usurped by the extra pair of ribs and the naming shifted caudally.

There was no specimen presenting seven pairs of Nn. spinales lumbales.

N. genitalis (N. spermaticus externus) was formed by:

L ₂ , L ₃	in 2 cases
L ₂ , L ₃ , L ₄	in 2 cases
L ₃ , L ₄	in 10 cases.

The most common contributor to the nerve was the L₃.

N. cutaneus femoris lateralis was formed by:

L ₂ , L ₃	in 2 cases
L ₂ , L ₃ , L ₄	in 1 case
L ₃ , L ₄	in 11 cases.

Although L₃ appears to have contributed more frequently than any other, the main contributor was the L₄. The N. cutaneus femoris lateralis, in addition to the destination bearing its name, innervates part of the paralumbar and inguinal region. It almost always exchanges fibers with the N. genitalis (N. spermaticus externus).

N. femoralis was formed by:

L ₃ , L ₄	in 1 case
L ₃ , L ₄ , L ₅	in 6 cases
L ₄ , L ₅	in 4 cases
L ₄ , L ₅ , L ₆	in 3 cases.

In this nerve the L₅ was the main root but the L₄ had contributed equally in more than half of the cases.

N. obturatorius was formed by:

L ₃ , L ₄	in 1 case
L ₃ , L ₄ , L ₅	in 5 cases
L ₃ , L ₄ , L ₅ , L ₆	in 1 case
L ₄ , L ₅	in 2 cases
L ₄ , L ₅ , L ₆	in 5 cases.

In this nerve the L_4 and the L_5 were the main contributors.

N. glutaesus cranialis was formed by:

L_3, L_4, L_5	S_1, S_2	in 1 case
L_4, L_5, L_6, S_1		in 1 case
L_5, L_6, S_1		in 8 cases
L_5, L_6, S_1, S_2		in 4 cases

In this nerve the L_5, L_6 and S_1 are the main contributors.

N. glutaesus caudalis was formed by:

L_3, L_4, L_5	S_1, S_2	in 1 case
L_5, L_6, S_1, S_2		in 10 cases
L_6, S_1, S_2		in 3 cases

Here again it is the S_1 and S_2 which are the predominant contributors to N. glutaesus caudalis.

N. ischiadicus was formed by:

L_3, L_4, L_5	S_1, S_2	in 1 case
$L_3, L_4, L_5, L_6, S_1, S_2$		in 1 case
L_4, L_5, L_6, S_1, S_2		in 2 cases
L_5, L_6, S_1, S_2		in 10 cases

As can be deduced from these figures the L_5, L_6, S_1 and S_2 are the most common contributors to the N. ischiadicus.

N. splanchnicus pelvinus was formed by:

S_1, S_2	in 3 cases
S_2, S_3	in 12 cases

In this nerve the figures show the S_2 to be the central

core to which others converge, but it is safe to say that the S_2 and S_3 are the main contributors.

N. pudendus was formed by:

S_1, S_2, S_3	in 1 case
S_2, S_3	in 11 cases
S_2, S_3, S_4	in 3 cases

This nerve is obviously formed by the S_2 and S_3 in most of the cases. The N. pudendus terminates by dividing into the Nn. clitoridus and mammarius in the female, or the Nn. dorsalis penis and scrotalis medius in the male.

N. cutaneus femoris caudalis was formed by:

S_1, S_2	in 1 case
S_1, S_2, S_3	in 3 cases
S_2	in 5 cases
S_2, S_3	in 6 cases

Again here the S_2 and S_3 are the main contributors to the N. cutaneus femoris caudalis.

Nn. rectales were formed by:

S_1, S_2, S_3, S_4	in 1 case
S_2, S_3, S_4	in 11 cases
S_3, S_4	in 3 cases

By virtue of the communications which the N. pudendus has with the S_4 , it can be said that the Nn. rectales are formed mainly by the S_3 and S_4 .

The Nn. perineales have similar origins to those of the

N. pudendus, and it should be remembered that they also receive a constant contribution by means of the communicating branch from the N. ischiadicus to the N. pudendus, which allows nerve fibers from the lumbar region to reach the perineum.

The N. dorsalis penis has a spiral and wavy course on the corpus cavernosum.

The Autonomic Nerves

Observations were made on the sympathetic trunks in the lumbar and pelvic regions including the coccygeal area. The general arrangement of the ganglia in the sympathetic trunks, and the collateral ganglia in the abdomen and pelvis were investigated. The relationship of the sympathetic and parasympathetic nerves in the formation of the abdominal and pelvic plexuses was investigated. This was carried out on seven specimens.

There were constantly six pairs of sympathetic ganglia in the lumbar region, four pairs in the sacral and between four to six macroscopically visible pairs of sympathetic ganglia in the coccygeal region. Although there was one case in which the first and second sacral pairs had fused on their respective sides, there was no such tendency in the lumbar area, instead a ganglion paravertebrale accessorium was found at the lumbosacral disc on the right side.

The G. coeliacus and a mesentericus cranialis of each side joined into a G. coeliacomesentericus by means of transverse fibers.

A G. renalis was present on the left side, but the Plexus renalis on the right side appeared to come off the caudal border of the G. coeliacomesentericus.

A G. genitalis was present on both sides, but in one case it was fused with the G. mesentericus caudalis. The latter, in some cases, fused closely, but in other cases they remained conspicuously separate.

From the fused G. mesentericus caudalis arise the N. hypogastricus, N. genitalis, Plexus mesentericus caudalis and Plexus uretericus.

The G. genitalis gave rise to the N. utero-ovaricus in the female and the N. testicularis in the male. They follow their respective arteries.

The N. hypogastricus traverses along layers of the peritoneum to meet the N. splanchnicus pelvinus arising from the sacral roots of the spinal nerves to form the Plexus pelvinus in the area of the neck of the bladder.

Often the N. pudendus gives off a branch which continues its course in a cranial direction and joins the Plexus pelvinus. On its course it innervates the striated muscles of the urogenital tract as far cranial as the neck of the bladder.

From the Plexus pelvinus arise the secondary plexuses to the bladder, the urethra, the accessory sex glands, the neck, body and caudal part of the horns of the uterus, the vagina, and the ductus deferens. A fairly large fiber passes caudally along the rectum to innervate the middle part of the *M. retractor penis* and partly penetrates the wall of the rectum to innervate the *M. sphincter ani internus*.

There were two cases, one in the sacral region and one in the coccygeal region, in which the sympathetic ganglia joined to produce a *Ganglion impar*. In the former case it occurred at the third pair of sacral sympathetic ganglia and in the latter case it was at the fourth pair of the coccygeal ganglia. In the sacral instance the *trunci sympathici* ran separately from the fused ganglia, with large ganglia discernable up to the second coccygeal vertebra, after which the ganglia were too small to observe macroscopically. However, the trunks joined at the fourth coccygeal vertebra. From here the behavior of the trunk in both cases was similar. The *A. coccygea mediana* is enclosed by a meshwork of fibers from these trunks.

The *Rami communicantes* were commonly paired in the lumbar region, and on very rare occasions at the first sacral sympathetic ganglia.

The *Rami communicantes transversi* were not observed in the lumbar region, but were irregularly found in the sacral and coccygeal regions.

In order to determine a statistically significant figure for the number of lumbar spinal nerves, more specimens need to be investigated, as well as various breeds. The results of this limited study emphasize the fact that there exists a wide variation in the origin of the component rami which form the lumbar nerves.

BIBLIOGRAPHY

- Allam, Mark W., Nulsen, Frank E., and Lewey, F. H. 1949. Electrical interneural bipolar stimulation of peripheral nerves in the dog. American Veterinary Association Journal 139: 87-89.
- Arnold, J. P. and Kitchell, R. L. 1957. Experimental studies of the innervation of the abdominal wall of cattle. American Journal of Veterinary Research 18: 229-240.
- Botár, J. 1932. Die Anatomie des lumbosacralen und coccygealen Abschnittes des Truncus sympathicus bei Haussäugetieren. Zeitschrift für Anatomie 97: 382-824.
- Brain, Peter G. P. 1949. Some observations on the technique of paravertebral anaesthesia. Veterinary Record 61: 88.
- Brash, J. C. and Jamieson, E. B., eds. 1937. Cunningham's textbook of anatomy. 7th ed. New York, New York, Oxford University Press.
- Broek, A. J. P. 1908. Untersuchungen über den Bau des sympathischen Nervensystems der Säugetiere. II. Morphologisches Jahrbuch 38: 532-589.
- Brook, G. B. 1935. Spinal (epidural) anaesthesia in domestic animals. Veterinary Record 15: 597-608. 634.
- Chauveau, A. and Arloing, S. 1902. The comparative anatomy of the domesticated animals. 2nd ed. New York, New York, D. Appleton.
- Christensen, G. C. and Dougherty, R. W. 1955. A simplified apparatus for obtaining semen from dogs by electrical stimulation. American Veterinary Medical Association Journal 127: 50-52.
- Cleland, J. P. G. 1933. Paravertebral anaesthesia in obstetrics. Surgery Gynecology and Obstetrics 57: 51-62.
- Cloninger, G. L. and Green, G. D. 1955. Pathways taken by the sympathetic vasomotor nerves from the sympathetic chain to the vasculature of the hind leg muscles of the dog. American Journal of Physiology 181: 258-262.

- Crossby, Elizabeth C., Humphrey, Trephena, and Lauer, Edward W. 1962. Correlative anatomy of the nervous system. New York, New York, The Macmillan Company.
- Dyce, K. M. 1958. The splanchnic nerves and the major abdominal ganglia of the horse. *Journal of Anatomy* 92: 60-73.
- Dziuk, P. J., Graham, E. F., Donker, J. D., Marion, G. B., and Petersen, W. E. 1954a. Some observations in collection of semen from bulls, goats, boars and rams by electrical stimulation. *Veterinary Medicine* 49: 455-458.
- Dziuk, P. J., Graham, E. F., and Peterson, W. E. 1954b. The technique electroejaculation and its use in dairy bulls. *Journal of Dairy Science* 37: 1035-1041.
- Edgeworth, F. H. 1892. On a large-fibered sensory supply of the thoracic and abdominal viscera. *Journal of Physiology* 13: 260-271.
- Ellenberger, W. and Baum, H. 1943. *Handbuch der vergleichenden Anatomie der Haustiere*. 18th ed. Berlin, Germany, Springer Verlag.
- Farquharson, J. 1940. Paravertibral lumbar anaesthesia in the bovine species. *American Veterinary Medical Association Journal* 97: 54-57.
- Fawcett, E. 1895. An unusual mode of site of termination of the right sacral sympathetic cord in man. *Journal of Anatomy and Physiology* 29: 329.
- Fischer, J. 1906. Vergleichend anatomische und histologische Untersuchungen über den N. sympathicus einiger Tiere, insbesondere der Katze und Ziege. *Archiv für wissenschaftliche praktische Tierheilkunde* 32: 89-106.
- Frewein, J. 1962. Die Partes abdominalis, pelvina und coccygea systematis autonomici und deren periphere Geflechte bei *Bos taurus* L. *Gegenbaurs Morphologisches Jahrbuch* 103: 361-408.
- Gaskell, W. H. 1886. On the structure, distribution and function of the nerves which innervate the visceral and vascular systems. *Journal of Physiology* 7: 1-80.
- Getty, R. 1963. Epidural anaesthesia in the hog; its technique and applications. *American Veterinary Medical Association, Scientific Proceedings* 100: 89-98.

- Goglia, G. 1956. Ricerche topografiche sulla distribuzione regionale delle spansioni nervose sensitive nel dei Suini. Quaderni di Anatomia Practica 2: 337-360.
- Goller, H. 1959. Vergleichende Rückenmarktopographie unser Haustiere. Tierärztliche Umschau 14: 107-110.
- Gray, Henry and Lewis, Warren H. rev. 1918. Anatomy of the human body. 20th ed. Philadelphia, Pennsylvania, Lea and Febiger.
- Habel, R. E. 1951. Guide to the dissection of the cow. 2nd ed. Ithaca, New York, Comstock Cooperative Society.
- Habel, R. E. 1956. A source of error in the pudendal nerve block. American Veterinary Medical Association Journal 128: 16-17.
- Heinze, W. 1964. Die Muskulatur der Hintergliedmasse von Giraffa camelopardalis angoliensis mit einigen Hinweisen zur Blutgefäße und Nervenversorgung. Anatomischer Anzeiger 115: 476-496.
- Hopkins, G. S. 1935. The correlation of anatomy and epidural anaesthesia in domestic animals. Cornell Veterinarian 25: 263-270.
- House, E. L. and Pansky, B. 1960. A functional approach to neuroanatomy. New York, New York, The Blackiston Division, McGraw-Hill Book Company Inc.
- Jankovic, Z. K. 1954. Das Rückenmark, die Rückenmarkshüllen, ihre Zwischenräume und ihre Topographie bei den Schwiänen. Original not available; cited in Goller, H. 1959. Vergleichende Rückenmarktopographie unserer Haustiere. Tierärztliche Umschau 14: 109.
- Kitchell, R. L., Campbell, B., Quilliam, T. A., and Larson, L. L. 1955. Neurological factors in sexual behavior of domestic animals. American Veterinary Medical Association Proceedings 92: 177-189.
- Kuntz, Albert. 1953. The autonomic nervous system. 4th ed. rev. Philadelphia, Pennsylvania, Lea and Febiger.
- Kuntz, Albert. 1956. Components of splanchnic and inter-mesenteric nerves. Journal of Comparative Neurology 105: 251-268.

- Langley, J. N. and Anderson, H. K. 1895. The innervation of the pelvic and adjoining viscera. III. The external generative organs. *Journal of Physiology* 19: 85-121.
- Langley, J. N. and Anderson, H. K. 1896. The innervation of the pelvic and adjoining viscera. *Journal of Physiology* 20: 372-406.
- Larson, L. L. 1953. Internal pudendal (Pudic) nerve block for the anaesthesia of the penis and relaxation of the retractor penis muscle. *American Veterinary Medical Association Journal* 123: 18-21.
- Larson, L. L. and Kitchell, R. L. 1958. Neural mechanisms in sexual behavior. II. Gross neuroanatomical and correlative neurophysiological studies of the external genitalia of the bull and ram. *American Journal of Veterinary Research* 19: 853-865.
- Larson, L. L., Kitchell, R. L., and Campbell, Berry. 1961. Neural mechanisms in sexual behavior. III. Preputial muscles and their reflexes in bull calves and rams. *American Journal of Veterinary Research* 122: 37-42.
- Learmouth, J. R. and Markowitz, J. 1929. Studies on the function of the lumbar sympathetic outflow. I. The relation of the lumbar sympathetic outflow to the sphincter ani internus. *American Journal of Physiology* 89: 686-691.
- Leutert, Gerald. 1963. Die anatomischen Nomenklaturen von Basel, Jena, Paris in dreifacher Gegenüberstellung. Leipzig, Germany, Anatomisches Institut der Karl-Marx Universität.
- Libera, K. 1933. Ein Beitrag zur lumbalanästhesie beim Schwein. Dissertation Berlin. Original not available; reported in Westhues, Melchior and Fritsch, Rudolf. 1964. *Animal anaesthesia; local anaesthesia*. 1st English edition. p. 165-166. Philadelphia, Pennsylvania, J. B. Lippincott.
- Linzell, J. L. 1959. The innervation of the mammary glands in the sheep and goat with observations on the lumbosacral autonomic nerves. *Quarterly Journal of Experimental Physiology* 44: 160-170.
- Martin, P. 1923. *Lehrbuch der Anatomie der Haustiere*. Stuttgart, Germany, Verlag von Schickhardt und Edner.

- Medowar, J. L. 1927. Die Nerven des Uterus und Vagina des Hundes. *Zeitschrift fur Anatomie* 86: 776-785.
- Mehler, W. R. 1951. An analysis of the lumbar sympathetic trunk in the dog. *Anatomical Record* 109: 325.
- Mehler, W. R., Fischer, J. C. and Alexander, W. F. 1952. The anatomy and variation of the lumbosacral sympathetic trunk in the dog. *Anatomical Record* 113: 421-435.
- Miller, Malcolm E., Christensen, George C., and Evans, Howard E. 1964. *Anatomy of the dog*. Philadelphia, Pennsylvania, W. B. Saunders Company.
- Mizeres, N. J. 1955. The anatomy of the autonomic nervous system in the dog. *American Journal of Anatomy* 96: 285-318.
- Montané, L. and Bourdelle, E. 1920. *Anatomie Regionale des Animaux Domestiques*. Volume 4. Paris, France, Ballière et Fils.
- Nulsen, Frank E. and Lewey, F. H. 1947. Intraneural bipolar stimulation: a new aid in the assessment of nerve injuries. *Science* 106: 301-302.
- Nunez, Q. M. 1964. Blood vessels of the genitalia and accessory genital organs of swine (*Sus scrofa domestica*). Unpublished M.S. Thesis, Ames, Iowa, Iowa State University of Science and Technology.
- Oliveira, A. 1962. Anatomy of the lumbosacral plexus of the cat. [I] Origin of the genitofemoral nerve. *Veterinaria*, Rio de Janeiro 15: 27-36.
- Oliveira, A. 1962. Anatomy of the lumbosacral plexus of the cat. [II.] Origin of the lateral cutaneous femoral nerve. *Veterinaria*, Rio de Janeiro 15: 71-79.
- Oppenheimer, M. J. 1938. Autonomic control of the retractor penis muscle in the cat. *American Journal of Physiology* 122: 745-752.
- Patten, Bradley M. 1948. *The embryology of the pig*. 3rd ed. New York, New York, McGraw-Hill Book Company, Inc.

- Reimers, Hans. 1913. Der Plexus lumbalis und sacralis des Rindes und Schweines. Inaugural Dissertation. Leipzig, Germany, Library, University of Leipzig.
- Schaller, O. 1956. Die periphere sensible Innervation der Haut am Rumpfe des Rindes. Wiener tierärztliche Monatsschrift 43: 346-368.
- Schmidt, C. A. 1933. Distribution of vagus and sacral nerves to the large intestine. Society of Experimental Biology, New York, Proceedings 30: 739-740.
- Schneider, J. und Zintzsch, I. 1962. Die Leitungsanästhesie an den Extremitäten des Schweines. Zentralblatt für Veterinärmedizin 9: 59-74.
- Schreiber, Josef. 1954. Topographisch anatomischer Beitrag zur klinischen Untersuchung der Rumpfeingeweide des Rindes. Wiener tierärztliche Monatsschrift 40: 132-144.
- Schreiber, Josef. 1956. Die anatomischen Grundlagen der Leitungsanästhesie beim Rind. IV. Die Leitungsanästhesie der Nerven der Hinterextremität. Wiener tierärztliche Monatsschrift 43: 673-705.
- Sherrington, C. S. 1892. Notes on the arrangement of some of the motor fibers in the lumbosacral plexus. Journal of Physiology 13: 621-772.
- Sinclair, John G. 1937. Anatomy of the foetal pig. Ames, Iowa, Collegiate Press.
- Sisson, S. and Grossman, J. D. 1953. Anatomy of the domestic animals. 4th ed. Philadelphia, Pennsylvania, W. B. Saunders Company.
- St. Clair, L. E. 1940. The nerve supply to the bovine mammary gland. Unpublished M.S. thesis. Ames, Iowa, Library, Iowa State University of Science and Technology.
- Teitlebaum, H. 1942. The innervation of the adrenal gland. Quarterly Review of Biology 17: 135-148.
- Trumble, H. C. 1934. The plan of the visceral nerves in the lumbar and sacral outflows of the autonomic nervous system. British Journal of Surgery 21: 664-676.

- Uchida, Suemasa. 1929. Morphologische Studien über das sympathische Nervensystem des Schweines (*Sus asiaticus*). II. Mitteilung. Brust- und Bauchteil. Kyoto, Japan, Anatomical Institute, Imperial University.
- Westhues, Melchoir and Fritsch, Rudolf. 1964. Animal anaesthesia; local anaesthesia, 1st English edition. Philadelphia, Pennsylvania, J. B. Lippincott.
- Woollard, H. H. and Norrish, R. E. 1933. The anatomy of the peripheral sympathetic nervous system. *British Journal of Surgery* 21: 83-103.
- Wright, J. G. 1938. *Veterinary anaesthesia*. 2nd edition. Chicago, Illinois, Alexander Eger, Inc.
- Zintzsch, I. 1964. Morphologische Grundlagen der vegetativen Innervation der Beckenhöhlenorgane des Schafes (*Ovis aries* L.): der Grenzstrang und die Nn. pelvici. *Zentralblatt für Veterinärmedizin* 11, Reihe A: 647-667.

ACKNOWLEDGMENTS

The author expresses his gratitude to his major professor, Dr. R. Getty, whose counsel full of encouragement and constructive criticism is very deeply appreciated.

Much appreciation also is expressed to the author's graduate committee namely: Dr. R. Bryan, Dr. N. Cholvin and Dr. M. A. Emmerson.

A special word of gratitude is expressed to Dr. N. G. Ghoshal, a visiting professor from Bengal Veterinary College, Calcutta, India, for his relentless offer of his time to translate some of the German articles cited in this thesis.

Most of the excellent photographic work was done by Dr. D. J. Hillmann, and the illustrative drawings by Mrs. R. Guenther, to both of whom much appreciation is expressed.

Partial financial support was received from the Veterinary Medical Research Institute of Iowa State University which is acknowledged with appreciation.

Acknowledgment is extended to the author's sponsors, the Rockefeller Foundation for providing the financial support throughout the period of study. In this connection is included the author's Dean of the Veterinary School, Nairobi, East Africa, then Dr. J. B. Polding, who recommended his leave to carry out this study.

The Giessen Institute of Anatomy is acknowledged for having agreed to send over Dr. R. Hofmann to carry on the teaching while the author was away, and the Government of West Germany Republic which sustained the financial obligation is similarly acknowledged.

Acceptance of the author by the Graduate College at Iowa State University of Science and Technology is indeed an appreciable act of goodwill.

The author wishes to express the loving encouragement of his wife, Sarah, who, although away at home in Uganda, kept the author's morale high by regular communication through letter writing expressing incessant prayers for his success.

132a

APPENDIX A

Table 1. Comprehensive table for specimens examined showing the origin of somatic nerves in lumbar and sacral regions

A ^a	B	C ^b	D	E	F	G	H	I
1	Yorkshire	M-	180 lb	8 mo	6	L _{3,4}	L _{3,4}	L _{4,5}
2	Yorkshire	M-	195 lb	9-1/2 mo	6	L _{2,3,4}	L _{2,3,4}	L _{4,5}
3	Yorkshire	F	183 lb	10 mo	6	L _{3,4}	L _{3,4}	L _{4,5}
4	Yorkshire	F	590 lb	6-1/2 yr	5	L _{2,3}	L _{2,3}	L _{3,4}
5	Landrace	F	529 lb	6-1/2 yr	6	L _{3,4}	L _{3,4}	L _{3,4,5}
6	York-Landrace	F	452 lb	2-1/2 yr	6	L _{2,3}	L _{2,3}	L _{3,4,5}
7	York-Landrace	F	410 lb	2 yr	6	L _{3,4}	L _{3,4}	L _{3,4,5}
8	York-Landrace	F	535 lb	2 yr	6	L _{3,4}	L _{3,4}	L _{4,5}
9	Poland-China	M	729 lb	5 yr	6	L _{3,4}	L _{3,4}	L _{3,4,5}
10	York-Landrace	M-	175 lb	8 mo	6	L _{3,4}	L _{3,4}	L _{3,4,5}
11	Yorkshire	M	30 lb	3 mo	6	L _{3,4}	L _{3,4}	L _{4,5,6}
12	Yorkshire	M	60 lb	4 mo	6	L _{2,3,4}	L _{3,4}	L _{4,5,6}
13	Poland-China	M-	150 lb	6 mo	6	L _{3,4}	L _{3,4}	L _{3,4,5}
14	Yorkshire	F	658 lb	6 yr	6			
15	Poland-China	F	180 lb	8 mo	6	L _{3,4}	L _{3,4}	L _{4,5}

^aA-Specimen no.; B-Breed; C-Sex; D-weight; E-Age; F-No. lumbar nerves; G-N. genitalis; H-N. cut. fem. lateralis; I-N. femoralis; J-N. obturatorius; K-N. glut. cranialis; L-N. glut. caudalis; M-N. ischiadicus; O-N. pudendus; P-N. cut. fem. caudalis; Q-N. rectalis caudalis.

^bF = female; M = male; M- = male castrated.

J	K	L	M	N	O	P	Q
L _{4,5,6}	L _{5,6} S ₁	L _{5,6} S _{1,2}	L _{5,6} S _{1,2}	S _{2,3}	S _{2,3}	S _{2,3}	S _{3,4}
L _{4,5,6}	L _{5,6} S ₁	L _{5,6} S _{1,2}	L _{5,6} S _{1,2}	S _{2,3}	S _{2,3}	S _{2,3}	S _{2,3,4}
L _{4,5,6}	L _{5,6} S ₁	L _{5,6} S _{1,2}	L _{5,6} S _{1,2}	S _{2,3}	S _{2,3}	S _{2,3}	S _{2,3,4}
L _{3,4}	L _{3,4,5} S _{1,2}	L _{3,4,5} S _{1,2}	L _{3,4,5} S _{1,2}	S _{2,3,4}	S _{1,2,3}	S _{1,2,3}	S _{2,3,4}
L _{3,4,5,6}	L _{5,6} S ₁	L _{5,6} S _{1,2}	L _{5,6} S _{1,2}	S _{2,3}	S _{2,3}	S _{1,2,3}	S _{3,4}
L _{3,4,5}	L _{5,6} S ₁	L _{5,6} S _{1,2}	L _{5,6} S _{1,2}	S _{2,3}	S _{2,3}	S _{2,3}	S _{2,3,4}
L _{3,4,5}	L _{5,6} S ₁	L _{5,6} S _{1,2}	L _{5,6} S _{1,2}	S _{2,3}	S _{2,3}	S _{1,2,3}	S _{2,3,4}
L _{4,5}	L _{5,6} S _{1,2}	L _{5,6} S _{1,2}	L _{4,5,6} S _{1,2}	S _{2,3}	S _{2,3}	S ₂	S _{2,3,4}
L _{3,4,5}	L _{5,6} S ₁	L _{5,6} S _{1,2}	L _{3,4,5,6} S _{1,2}	S _{1,2}	S _{2,3}	S ₂	S _{2,3,4}
L _{3,4,5}	L _{5,6} S ₁	L ₆ S _{1,2}	L _{5,6} S _{1,2}	S _{1,2}	S _{2,3}	S _{2,3}	S _{2,3,4}
L _{4,5,6}	L _{5,6} S ₁	L ₆ S _{1,2}	L _{5,6} S _{1,2}	S _{2,3}	S _{2,3,4}	S _{2,3}	S _{2,3,4}
L _{4,5,6}	L _{5,6} S ₁	L ₆ S _{1,2}	L _{5,6} S _{1,2}	S _{2,3}	S _{2,3,4}	S ₂	S _{2,3,4}
L _{3,4,5}	L _{4,5,6} S ₁	L _{5,6} S _{1,2}	L _{4,5,6} S _{1,2}	S _{1,2}	S _{1,2,3}	S ₂	S _{1,2,3,4}
	L _{5,6} S _{1,2}	L _{5,6} S _{1,2}	L _{5,6} S _{1,2}	S _{2,3}	S _{2,3}	S _{1,2}	S _{3,4}
L _{4,5,6}	L _{5,6} S _{1,2}	L _{5,6} S _{1,2}	L _{5,6} S _{1,2}	S _{2,3}	S _{2,3}	S ₂	S _{2,3,4}

Table 2. Distribution of the roots which form the somatic nerves in the lumbar^a and sacral^b regions

Name of nerve	L ₁	L ₂	L ₃	L ₄	L ₅	L ₆	L ₇	S ₁	S ₂	S ₃	S ₄	Cases
N. iliohypogastricus +												14
N. ilioinguinalis		+										14
N. genitalis		+	+									2
(N. spermaticus externus)		+	+	+								2
				+	+							10
N. cutaneus femoris		+	+									2
lateralis		+	+	+								1
				+	+							11
N. femoralis			+	+								1
			+	+	+							6
				+	+							4
				+	+	+						3
N. obturatorius			+	+								1
			+	+	+							5
			+	+	+	+						1
				+	+							2
				+	+	+						5
N. glutaenus cranialis			+	+	+	+		+	+			1
				+	+	+		+				1
					+	+		+				8
					+	+		+	+			4
N. glutaenus caudalis			+	+	+			+	+			1
					+	+		+	+			10
						+		+	+			3
N. ischiadicus			+	+	+			+	+			1
			+	+	+	+		+	+			1
				+	+	+		+	+			2
					+	+		+	+			10
N. splanchnicus pelvinus								+	+			3
									+	+		12

^a14 specimens.^b15 specimens.

Table 2. (Continued)

Name of nerve	L ₁	L ₂	L ₃	L ₄	L ₅	L ₆	L ₇	S ₁	S ₂	S ₃	S ₄	Cases
N. pudendus								+	+	+		1
									+	+		11
									+	+	+	3
N. cutaneus femoris								+	+			1
caudalis								+	+	+		3
									+			5
									+	+		6
Nn. rectales ^c								+	+	+	+	1
									+	+	+	11
										+	+	3

^cThe Nn. rectales include those other nerves that either join the S₄ or reach the same destination separately.

136a

APPENDIX B

Figure 1. The lumbosacral plexus of the pig, left side, ventral view

Specimen no. 2 ♂

- 1 Th = last thoracic spinal nerve - has a cutaneous branch and a branch to the Mm. obliquus externus abdominis, transversus abdominis and rectus abdominis
- 2 Cranial branch of N. iliohypogastricus - to the skin and M. obliquus externus abdominis
- 3 Caudal branch of N. iliohypogastricus - to the Mm. transversus abdominis and rectus abdominis
- 4 Cranial branch of N. ilioinguinalis - to M. obliquus externus abdominis and skin
- 5 Cranial intermediate branch of N. ilioinguinalis - to Mm. obliquus internus abdominis and rectus abdominis and skin
- 6 Caudal intermediate branch of N. ilioinguinalis - to Mm. obliquus internus abdominis, obliquus externus abdominis and skin
- 7 Caudal branch of N. ilioinguinalis - special to M. obliquus internus abdominis
- 8 Branches to Mm. psoas major and minor
- 9 N. genitalis (N. spermaticus externus)
- 9' Branch of 9 to M. obliquus internus abdominis
- 9" and 9"' Continuation of 9 through inguinal canal as N. inguinalis
- 10 N. cutaneus femoris lateralis
- 11 Branches to M. psoas major
- 12 N. femoralis
- 13 N. obturatorius
- 14 N. gluteus cranialis
- 15 N. ischiadicus
- 16 Communicating branch from N. ischiadicus to N. pudendus
- 17 N. pudendus
- 18 N. splanchnicus pelvinus
- 19 Nn. rectales caudales (Nn. haemorrhoidales caudales)
- L₁ - L₆ Ventral branches of Nn. spinales lumbales
- S₁ - S₄ Ventral branches of Nn. spinales sacrales

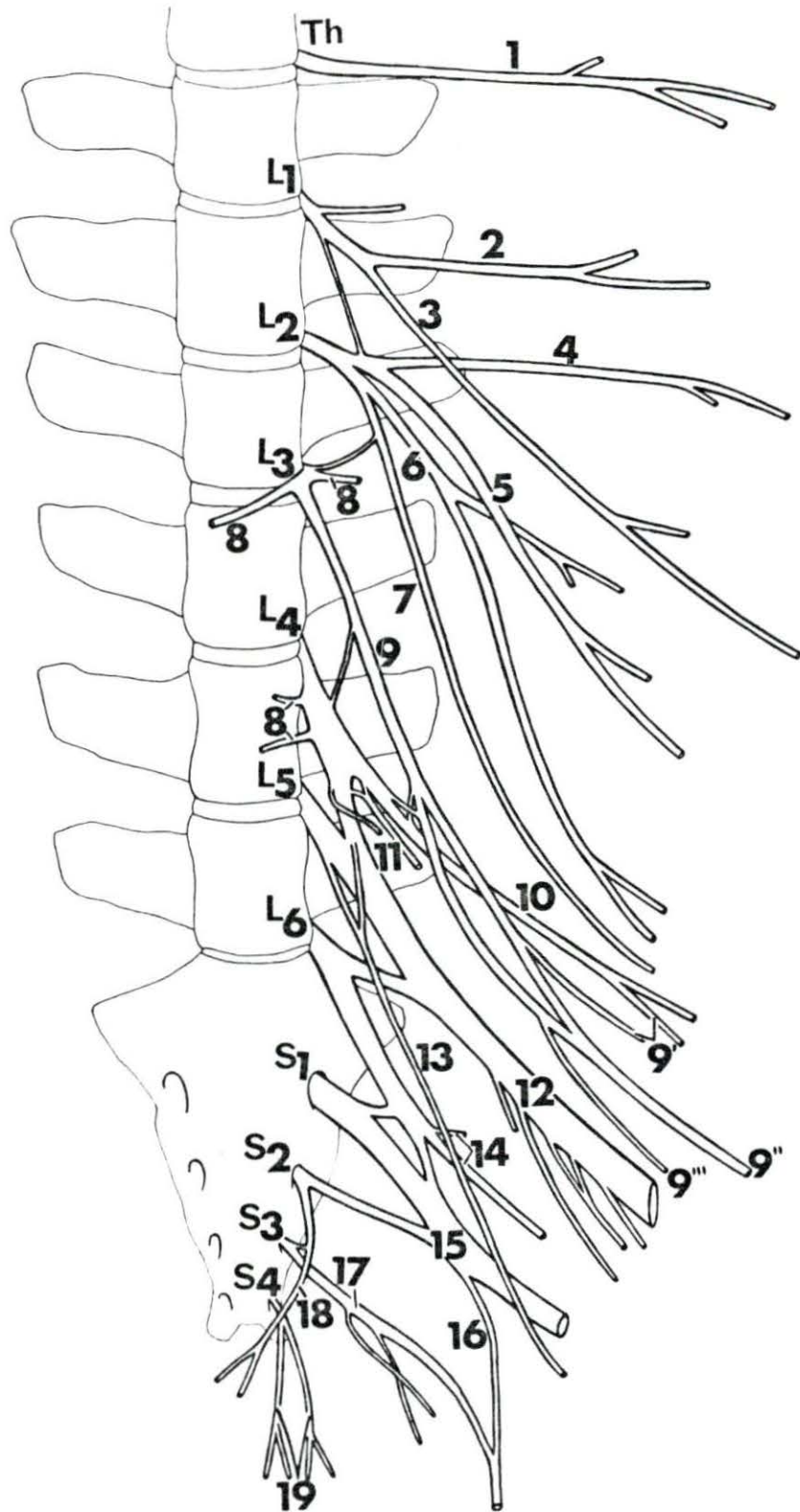


Figure 2. The lumbosacral plexus. Right side.

Specimen no. 3 ♀

- 1 N. genitalis (N. spermaticus externus)
 - 2 N. cutaneus femoris lateralis
 - 3 Branch of 2 to Mm. obliquus internus abdominis and cremastericus externus
 - 4 N. genitalis continued into the inguinal region
 - 5 N. femoralis
 - 6 N. obturatorius
 - 7 N. glutaeus cranialis
 - 8 N. ischiadicus
 - 9 N. glutaeus caudalis
 - 10 Communicating branch from N. ischiadicus to N. pudendus
 - 11 N. pudendus
 - 12 N. cutaneus femoris caudalis
 - 13 Branch of 11 to M. coccygeus
 - 14 Nn. rectales caudales (Nn. haemorrhoidales caudales) to M. levator ani and anal skin and a branch joining Nn. coccygei
 - 15 N. perinealis superficialis (N. labialis) from 11
 - 16 and 17 Nn perineales profunda from 11 to Mm. sphincter ani externus and constrictor vulvae and adjacent skin
 - 18 N. clitoridis from 11
 - 19 N. mammarius caudalis from 11
 - 20 Branch from 11 to urogenital tract
 - 21 N. splanchnicus pelvinus
 - 22 N. hypogastricus (sympathicus)
- L₃ - L₆ Ventral branches of Nn. spinales lumbales
S₁ - S₄ Ventral branches of Nn. spinales sacrales

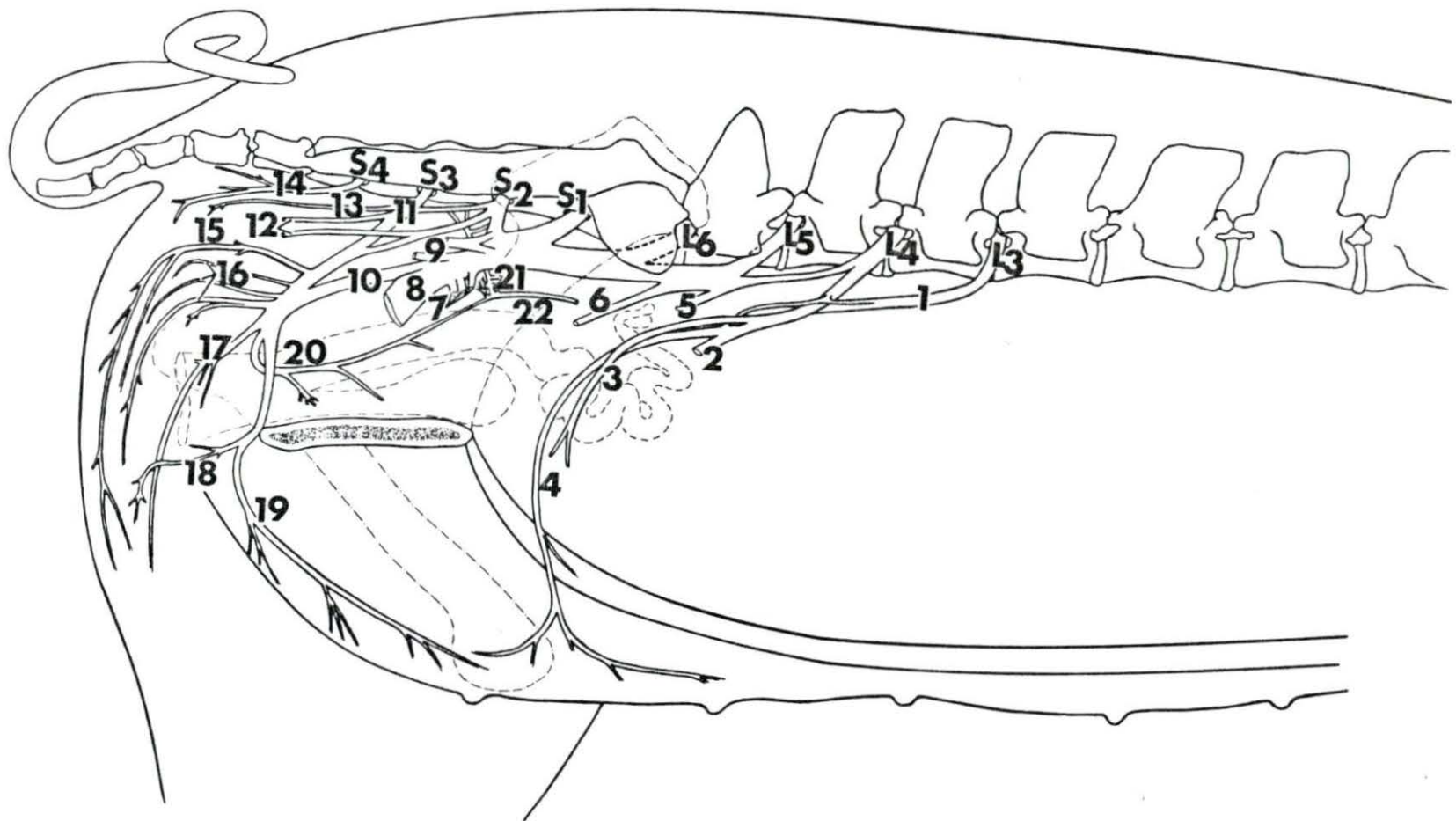


Figure 3. The lumbosacral plexus of the pig, left side

Specimen no. 3 ♀

- 1 N. iliohypogastricus
 - 2 N. ilioinguinalis
 - 3 Branch to M. psoas major
 - 4 Branch to M. obliquus internus abdominis
 - 5 N. genitalis (N. spermaticus externus)
 - 6 N. cutaneus femoris lateralis
 - 7 Branch to Mm. obliquus internus abdominis, and cremastericus externus
 - 8 Continuation of 5 (N. inguinalis)
 - 9 N. femoralis
 - 10 N. obturatorius
 - 11 N. glutaeus cranialis
 - 12 N. splanchnicus pelvinus
 - 13 N. pudendus
 - 14 Branch of 13 to M. coccygeus
 - 15 N. cutaneus femoris caudalis
 - 16 Nn. rectales (Nn. haemorrhoidales caudales) to M. levator ani and adjacent skin
 - 17 Branch from S₄ joining Nn. coccygei for ventral coccygeal muscles
 - 18 N. perinealis superficialis (N. labialis) from 13
 - 19 N. ischiadicus
 - 20 Communicating branch from N. ischiadicus to N. pudendus
 - 21 N. perinealis profundus to M. sphincter ani externus and M. constrictor valvae and adjacent skin
 - 22 N. clitoridis
 - 23 N. mammarius caudalis
 - 24 N. glutaeus caudalis
- L₁ - L₆ = ventral branches of Nn. spinales lumbales
S₁ - S₄ = ventral branches of Nn. spinales sacrales
Th = ventral branch of last thoracic spinal nerve

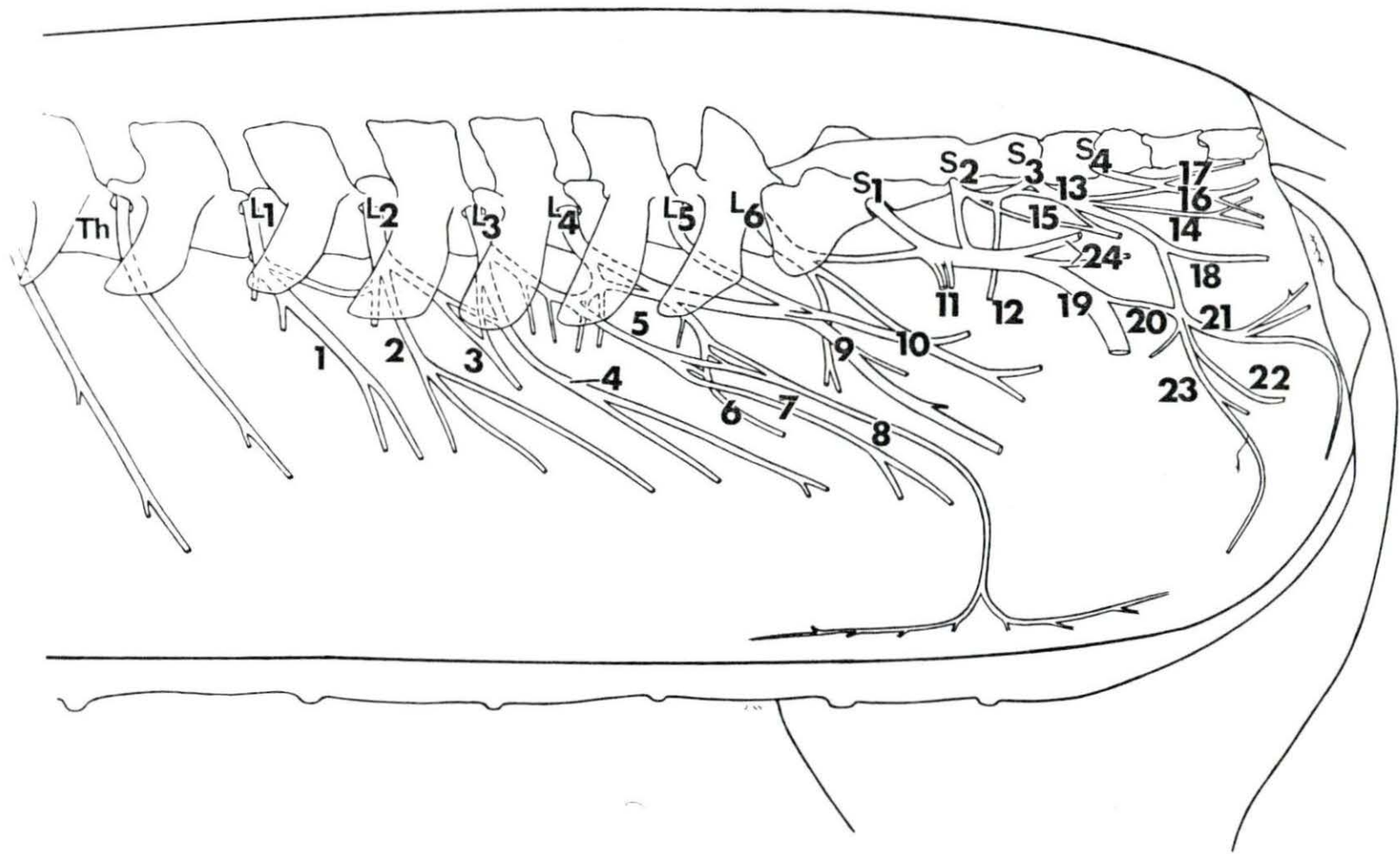


Figure 4. Ventral branches of the lumbar and sacral spinal nerves and the sympathetic trunk, ventral view

Specimen no. 4 ♀

- 1 N. ilioinguinalis
- 2 N. genitalis (N. spermaticus externus)
- 3 N. cutaneus femoris lateralis
- 4 N. femoralis
- 5 N. obturatorius
- 6 N. ischiadicus
- 7 N. pudendus
- 8 Communicating branch from N. ischiadicus to N. pudendus
- 9 N. cutaneus femoris caudalis
- 10 Branch of 7 to M. coccygeus
- 11 Nn. rectales caudales (Nn. haemorrhoidales caudales) to M. levator ani and anal skin
- 12 N. glutaesus cranialis
- 13 Truncus sympathicus
- 14 Ganglion sympathicum sacrale primum
- A Rudiments of last rib on left side
- B M. transversus abdominis
- C M. psoas major incised and displaced to the side to show the nerves innervating it
- L₁ - L₅ Ventral branches of Nn. spinales lumbales
- S₁ - S₄ Ventral branches of Nn. spinales sacrales
- Th Ventral branch of the last thoracic spinal nerve

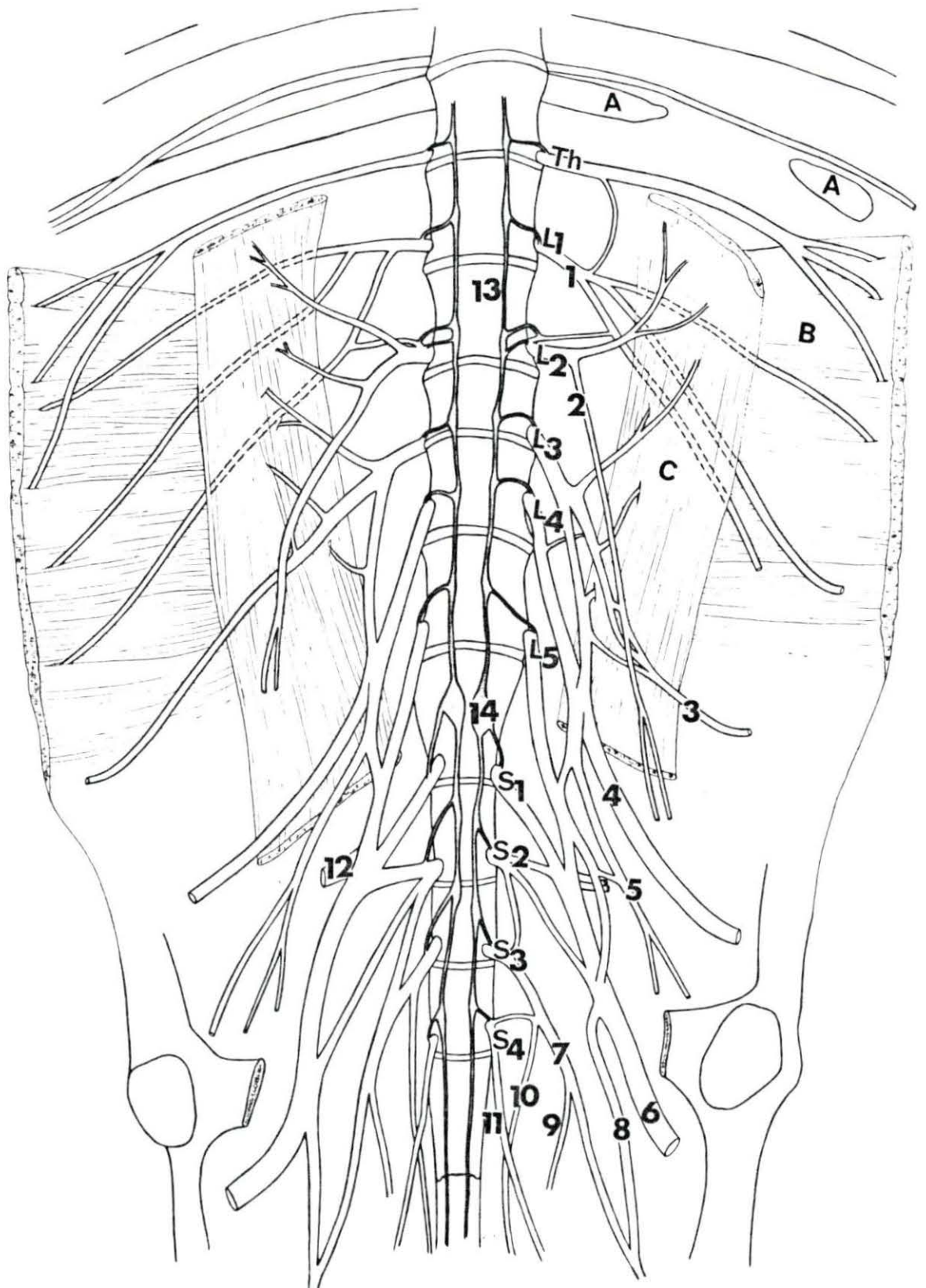


Figure 5. The lumbosacral plexus: nerves spread out, lateral view

Specimen no. 6 ♀

- | | | | |
|----|-------------------------------------------------------------------------------------------|--------------------------------|------------------------------------------------------------------------------|
| 1 | Ventral branch of last thoracic spinal nerve (Th) | 22 | Branch of N. pudendus to M. coccygeus |
| 2 | N. iliohypogastricus | 23 | N. cutaneus femoris caudalis |
| 3 | a,b,c, and d N. ilioinguinalis and its branches | 24 | N. pudendus |
| 4 | and 4a N. genitalis (N. spermaticus externus) and its continuation through inguinal canal | 25 | Nn. rectales caudalis (Nn. haemorrhoidales caudales) |
| 5 | N. cutaneus femoris lateralis | 26 | N. rectalis medius (N. haemorrhoidalis medius) |
| 6 | Branch of 4 and 5 forming N. inguinalis | 27 | N. perinealis superficialis (N. labialis) from 24 |
| 7 | Branch of 4 to M. ogliquus internus abdominis | 28 | N. perinealis profundus to Mm. sphincter ani externus and constrictor vulvae |
| 8 | Branch of 4 to M. cremastericus externus | 29 | N. clitoridis |
| 9 | Branch of N. femoralis to M. iliacus | 30 | N. mammarius caudalis |
| 10 | N. femoralis | L ₁ -L ₆ | Ventral branches of Mn. spinales lumbales |
| 11 | Branches of 10 to M. iliopsoas | S ₁ -S ₄ | Ventral branches of Nn. spinales sacrales |
| 12 | N. saphenus from 10 | | |
| 13 | Branches of 10 to M. quadratus femoris | | |
| 14 | N. obturatorius | | |
| 15 | N. ischiadicus | | |
| 16 | N. gluteus cranialis | | |
| 17 | N. gluteus caudalis | | |
| 18 | N. splanchnicus pelvinus | | |
| 19 | Communicating branch from N. ischiadicus to N. pudendus | | |
| 20 | Branch of N. pudendus to urogenital tract | | |
| 21 | N. hypogastricus (sympathicus) | | |




Figure 6. Arrangement of the dorsal branches of lumbar spinal nerves revealed after removal of *Mm. longissimus dorsi* and *multifidus dorsi*
Dorsolateral view

Specimen no. 7 ♀

- Th Dorsal branches of last two thoracic spinal nerves
- Th' Dorsomedial branch of the last thoracic spinal nerve
- Th'' Dorsolateral branch of the last thoracic spinal nerve
- L₁ - L₅ Dorsal branches of Nn. spinales lumbales
- A Remains of *M. longissimus dorsi*
- B *M. transversus abdominis*
- C *M. obliquus externus abdominis*
- D *M. obliquus internus abdominis*
- E *M. tensor fasciae latae*
- F. *M. glutaeus medius*, reflected
- G Ligsmenta intertransversaria
- H Ligaments interspinalia
- S Sacrum
- DS Dorsal spinous process of L₁ vertebra
- TP Transverse processes of lumbar vertebrae
- W Wing of Os ilium

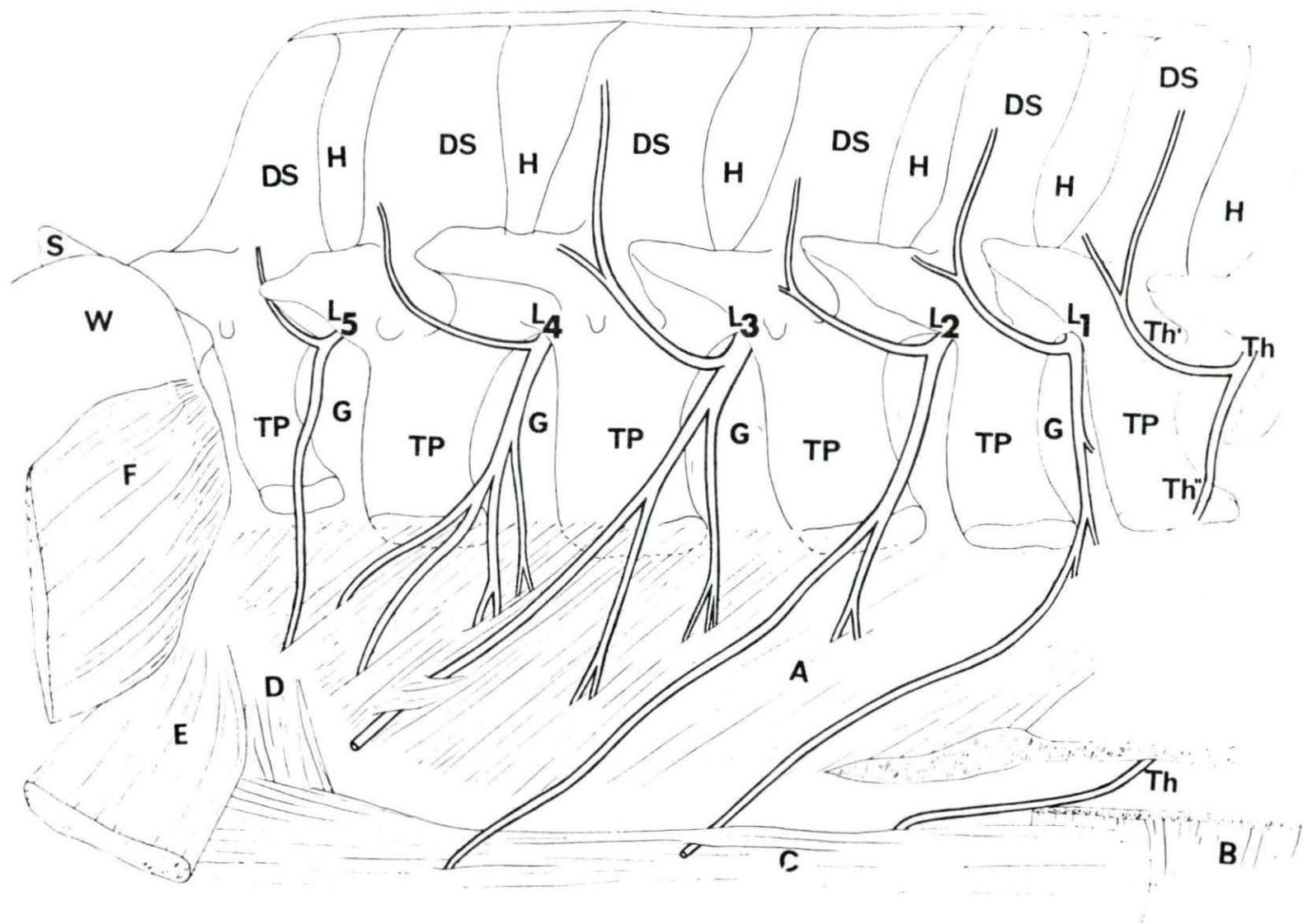


Figure 7. Superficial view revealing one of the modes of arrangement of the ventral branches of the lumbar spinal nerves in relation to Mm. psoas major and minor in Situ, right side
Ventral view

Specimen no. 6 ♀

- 1 Last intercostal nerve
 - 2 Ventral branch of last thoracic spinal nerve
 - 3 Ventral branch of L₁ spinal nerve
 - 4 and 5 Ventral branches of L₂ spinal nerve
 - 6 Communicating branch from L₃ spinal nerve to L₂ spinal nerve
 - 7 Ventral branch of L₃ spinal nerve (N. genitalis)
 - 8 Ventral branch of L₄ spinal nerve leading to N. cutaneus femoris lateralis
 - 9 Continuation of 7 as N. inguinalis
 - 10 Branch of 7 to M. cremaster externus
 - 11 Continuation of 8
 - 12 Branch of 7 to M. obliquus internus abdominis
- A Right crus of M. diaphragma
B M. psoas minor
C M. psoas major
D M. transversus abdominis
E M. quadratus lumborum
F M. obliquus internus abdominis
G M. rectus abdominis
H M. cremaster externus

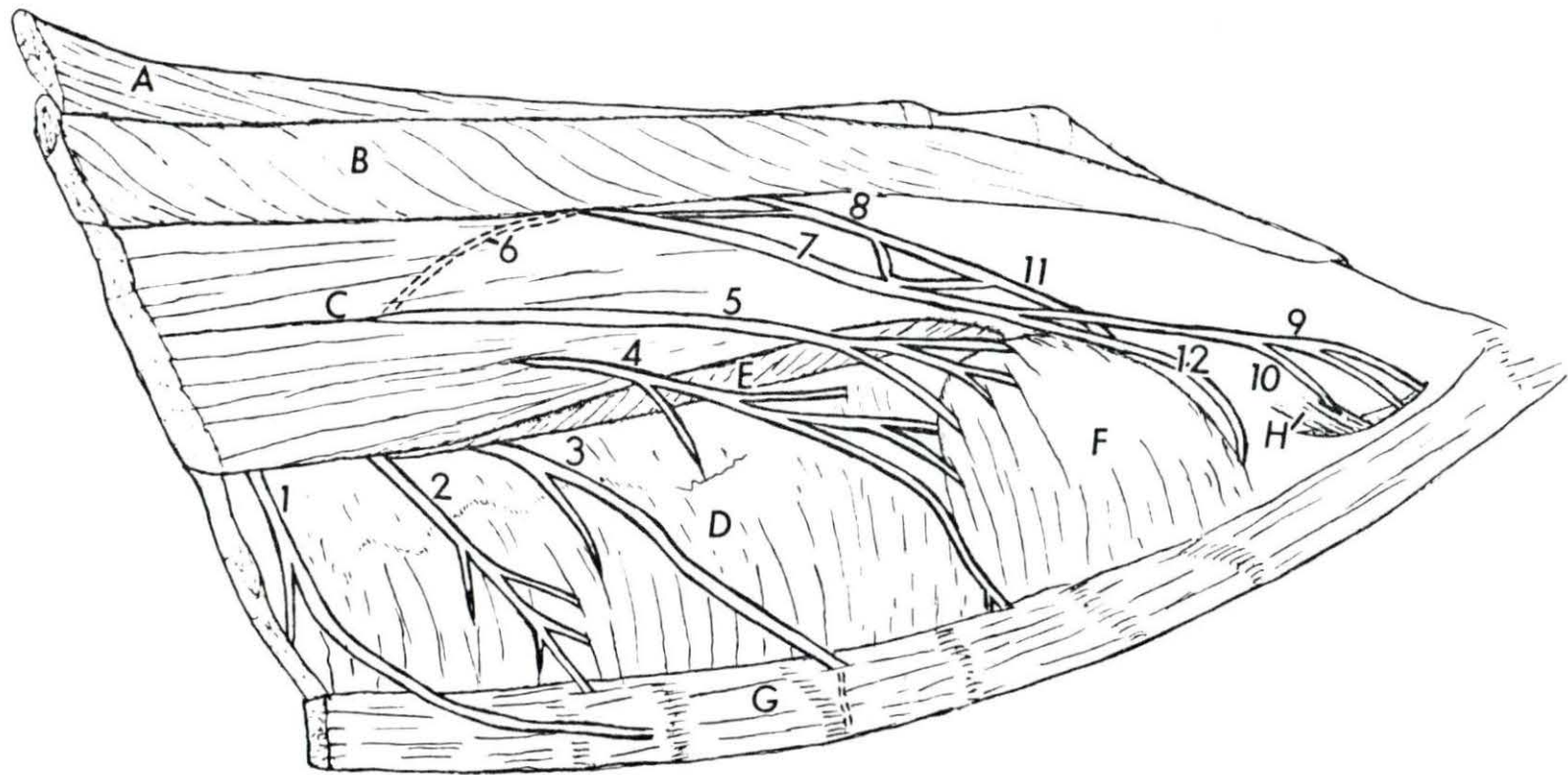


Figure 8. Deeper view of the arrangement of the ventral branches of lumbar spinal nerves after part of *M. psoas major* and *minor* have been removed to reveal loop formed between L_2 and L_3 spinal nerves, right side, ventral view

Specimen no. 6 ♀

- 1 Last intercostal nerve
- 2 Ventral branch of last thoracic spinal nerve
- 3 Ventral branch of L_1 spinal nerve
- 4 and 5 Ventral branches of L_2 spinal nerve
- 6 Communicating branch from L_3 to L_2 spinal nerves forming a loop
- 7 Ventral branch of L_3 spinal nerve (*N. genitalis*)
- 8 Ventral branch of L_4 spinal nerve (*N. cutaneus femoris lateralis*)
- 9 Continuation of 7 as *N. inguinalis*
- 10 Branch of 7 to *M. cremaster externus*
- 11 Continuation of 8
- 12 Branch of 7 to *M. obliquus internus abdominis*
- A Right crus of *M. diaphragm*, reflected
- B *M. psoas minor*
- C *M. psoas major*
- D *M. transversus abdominis*
- E *M. quadratus lumborum*
- F *M. rectus abdominis*
- G *M. obliquus internus abdominis*

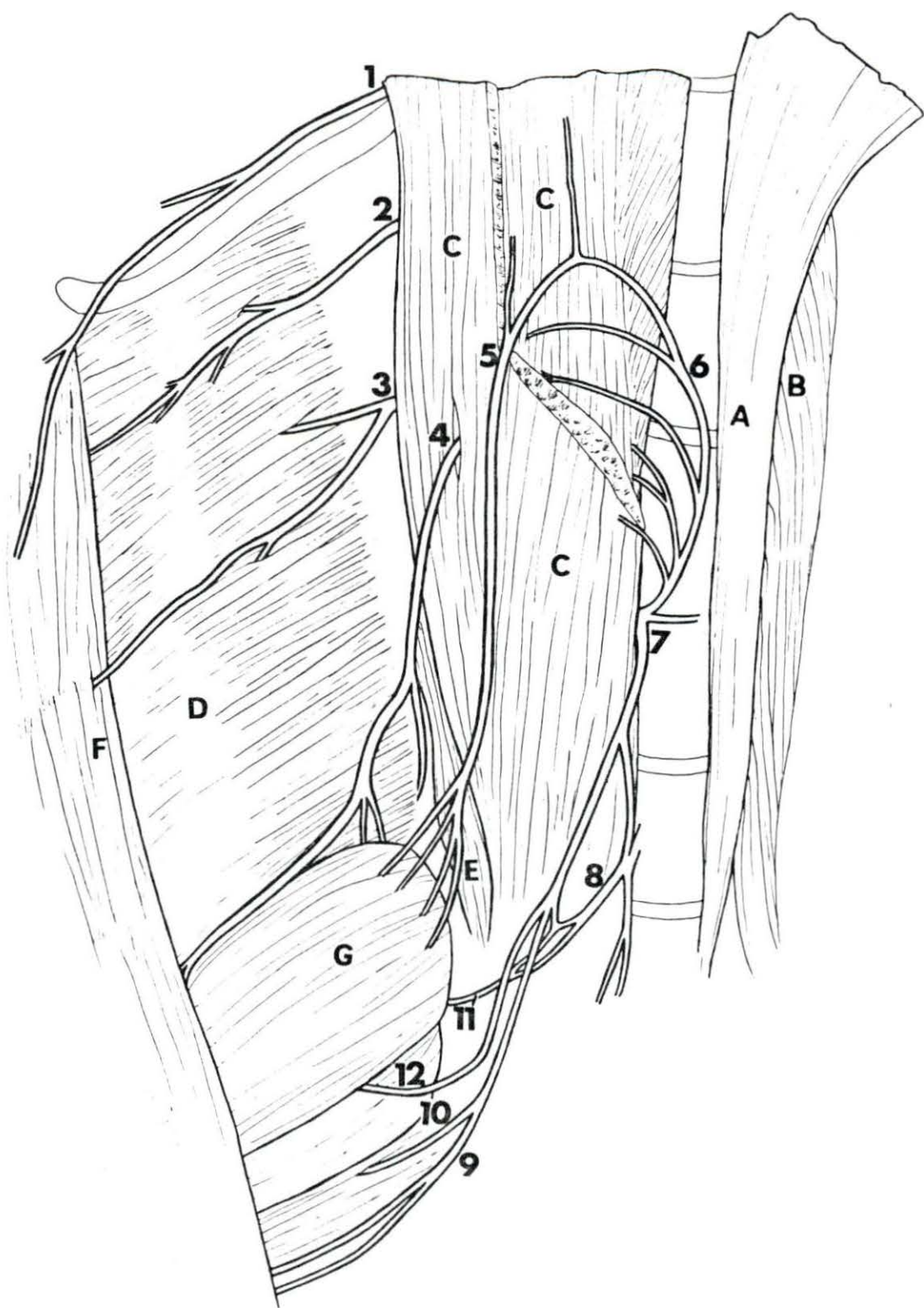


Figure 9. Another mode of arrangement of the ventral branches of the lumbar spinal nerves in relation to Mm. psoas major and minor in situ, ventral view

Specimen no. 8 ♀

- 1 Last intercostal nerve
 - 2 Ventral branch of last thoracic spinal nerve
 - 3 Ventral branches of L₁ spinal nerve
 - 4 Nerve formed by branches from both L₁ and L₂ spinal nerves
 - 5 Ventral branch from L₃ spinal nerve to M. obliquus internus abdominis
 - 6 Branch from L₃ spinal nerve to N. genitalis
 - 7 Ventral branch of L₄ spinal nerve to N. cutaneus femoris lateralis
 - 8 Continuation of 7
 - 9 Branch of 6 to M. obliquus internus abdominis
 - 10 Continuation of 6 through inguinal canal as N. inguinalis
 - 11 Branch of 6 to M. cremaster externus
- A M. psoas minor
B M. psoas major
C M. retractor costae
D M. transversus abdominis
E M. quadratus lumborum
F M. obliquus internus abdominis
H M. cremaster externus

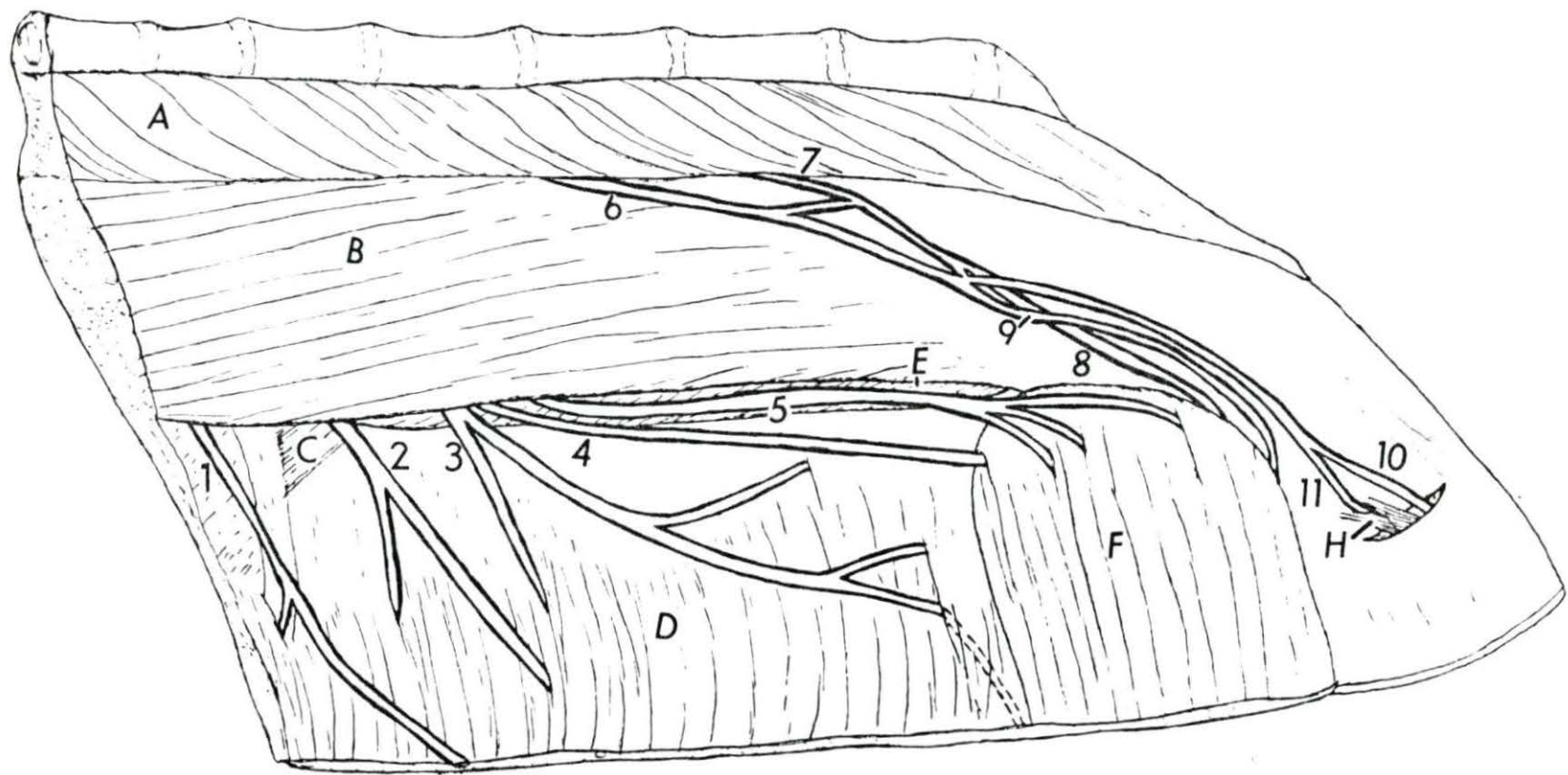


Figure 10. The gluteal region and the ischio-anal fossa, left side dorsolateral view

Specimen no. 8 ♀

- 1 N. ischiadicus
- 2 N. glutaesus caudalis
- 3 Communicating branch from N. ischiadicus to N. pudendus
- 4 N. cutaneus femoris caudalis
- 5 N. pudendus
- 6 Continuation of 5 to ramify as N. clitoridis and Ramus mammarius caudalis
- 7 Common trunk for Nn. perinei
- 8 N. perinealis superficialis (N. labialis) from 5
- 9 Dorsal branches of Nn. spinales sacrales
- 10 Dorsal branches of Nn. spinales coccygei
- A Lig. sacrospinotuberale
- B M. glutaesus profundus
- C M. obturatorius internus
- D M. coccygeus
- E M. levator ani (M. retractor ani, M. coccygeus medialis)
- F Mm. sphincter ani externus and constrictor vulvae
- G M. ischiocavernosus and constrictor vestibuli
- H Vulva
- I Subcutaneous anal fat
- J M. semimembranosus
- K M. semitendinosus
- L Tuber ischii

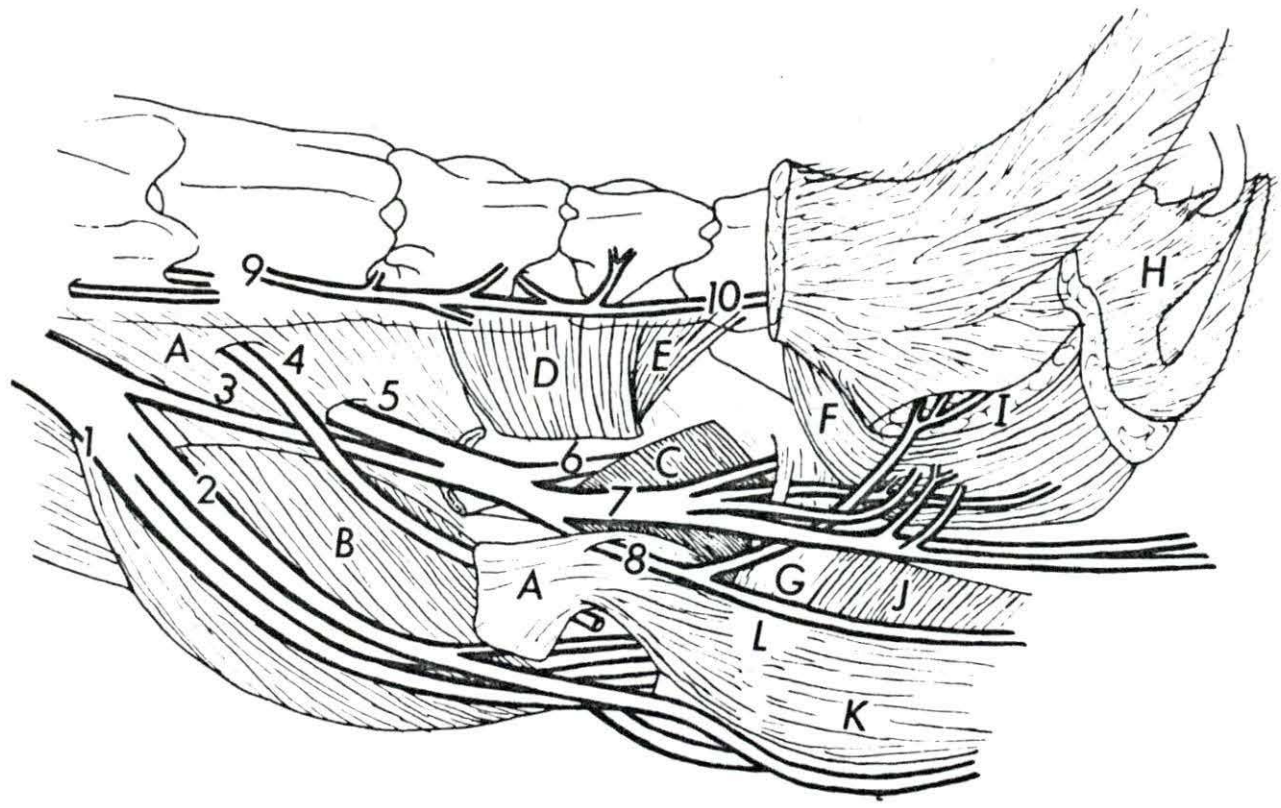


Figure 11. The roof of the pelvis showing sacral and some of the coccygeal nerves left side, ventral view

Specimen no. 8 ♀

- 1 N. femoralis
- 2 N. obturatorius
- 3 N. ischiadicus
- 4 N. cutaneus femoris caudalis
- 5 N. pudendus
- 6 Branch of 5 to M. coccygeus
- 7 Nn. rectales caudales (Nn. haemorrhoidales caudales)
- 8 Urogenital branch of 5
- 9 Origin of Nn. perinei from 5
- 10 Branch to Mm. constrictor vulvae and urethralis from 8
- 11 N. mammarius caudalis from 8
- 12 N. clitoridis from 8
- 13 N. splanchnicus pelvinis
- A N. obturatorius internus
- B Lig. sacrospinotuberale
- C M. coccygeus
- D M. biceps femoris
- E M. semitendinosus
- F M. semimembranosus
- G Mm. ischiocavernosus and constrictor vestibuli
- H Mm. sphincter ani externus and constrictor vulvae
- I Vagina
- J Rectum
- K Clitoris
- S₁ - S₄ Ventral branches of Nn. spinales sacrales
- Cy₁ and Cy₂ Ventral branches of Nn. spinales coccygei

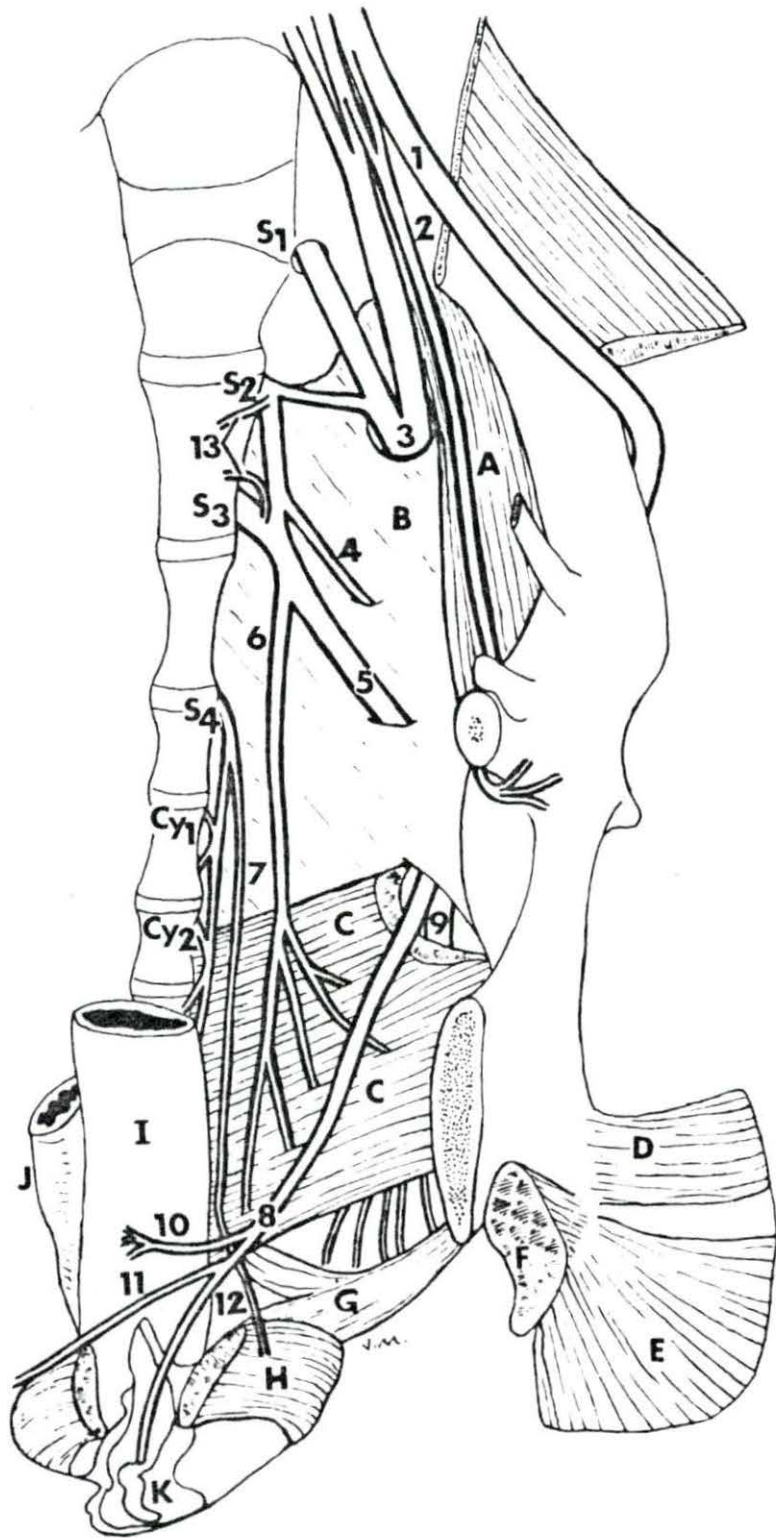


Figure 12. Paralumbar, gluteal and femoral regions, left side

Specimen no. 9 ♂

- | | | | |
|---------|------------------------------------------------------------------------------|---------------------------------|-----------------------------------------------------|
| 1 | Ventral cutaneous branch of the last thoracic spinal nerve | 24 | N. tibialis |
| 2 | Ventral cutaneous branch of L ₁ spinal nerve | 25 | N. fibularis (N. peroneus) |
| 3 and 4 | Ventral cutaneous branch of L ₂ spinal nerve | A | M. longissimus dorsi |
| 5 | N. cutaneus femoris lateralis | B | M. obliquus internus abdominis |
| 6 | N. glutaeus cranialis | C | M. obliquus externus abdominis |
| 7 | Branch of 6 to M. glutaeus profundus | D | M. iliacus |
| 8 | N. ischiadicus | E | M. vastus lateralis |
| 9 | N. glutaeus caudalis | F | M. biceps femoris |
| 10 | Communicating branch from N. ischiadicus to N. pudendus | G | M. gastrocnemius |
| 11 | N. pudendus | H | M. soleus |
| 12 | N. cutaneus femoris caudalis | J | M. semitendinosus |
| 13 | Branch of 11 to M. coccygeus | K | M. semimembranosus |
| 14 | Branch of 11 to urogenital tract | L | M. retractor penis |
| 15 | Continuation of 11 as N. dorsalis penis and N. scrotalis medius | M | M. levator ani (M. retractor ani, M. coccy. medius) |
| 16 | N. perinealis profundus | N | M. coccygeus |
| 17 | N. perinealis superficialis | O | Glandulae vesiculae seminales |
| 18 | Branch from S ₃ to M. sphincter ani externus (N. rectalis medius) | P | M. rectus femoris |
| 19 | N. rectalis caudalis (N. haemorrhoidalis caudalis) | Q | M. glutaeus profundus |
| 20 | Branch from 8 to proximal part of M. biceps femoris | R | M. sphincter ani externus |
| 21 | Branch from 8 to Mm. semitendinosus and semimembranosus | S | M. transversus abdominis |
| 22 | Branch of 8 to distal part of M. biceps femoris | S ₁ - S ₄ | Ventral branches of Nn. spinales sacrales |
| 23 | N. cutaneus surae caudalis medialis | Cyl | Ventral branch of N. spinalis coccygis |

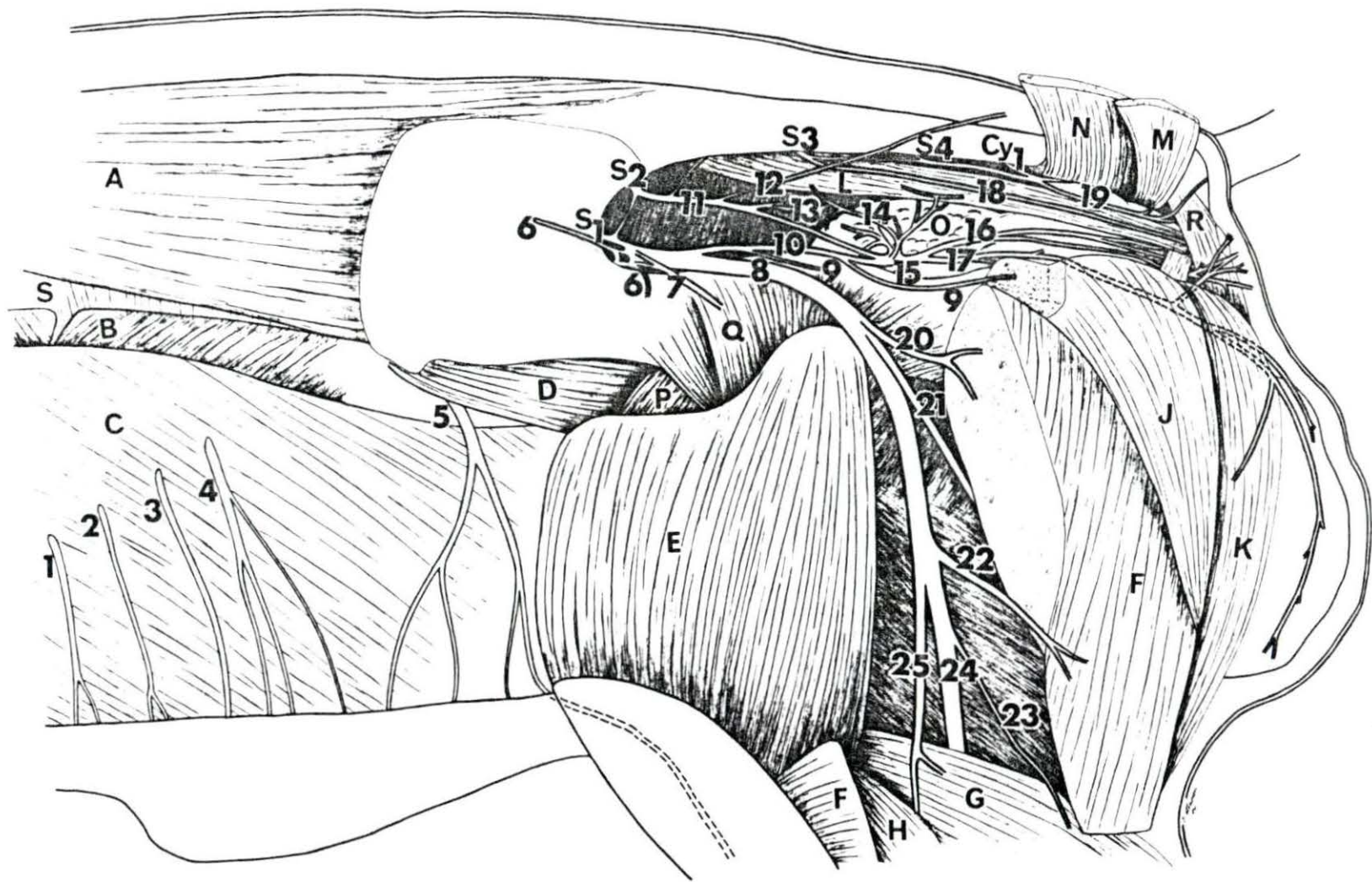


Figure 13. The lumbosacral plexus, left side, medial view

Specimen no. 9 6

- | | | | |
|----|----------------------------------------------------------|---------------------------------|---------------------------------------------------|
| 1 | N. iliohypogastricus | A | M. transversus abdominis |
| 2 | N. ilioinguinalis | B | M. rectus abdominis |
| 3 | N. genitalis (N. spermaticus externus) | C | M. quadratus lumborum |
| 4 | N. cutaneus femoris lateralis | D | Penis |
| 5 | Continuation of 3, N. inguinalis | E | M. cremaster externus |
| 6 | Branch of 3 to M. cremaster externus | F | M. retractor penis |
| 7 | N. femoralis | G | Gl. bulbourethralis |
| 8 | N. obturatorius | H | M. gracilis |
| 9 | N. ischiadicus | J | Urethra |
| 10 | N. splanchnicus pelvinus | K | Rectum |
| 11 | N. pudendus | M | M. obliquus internus abdominis |
| 12 | N. cutaneus femoris caudalis | N | Ligamentum inguinale |
| 13 | N. scrotalis medius (sinister) from
N. dorsalis penis | L ₁ - L ₆ | Ventral branches to Nn.
spinales sacrales |
| 14 | N. dorsalis penis from 11 | S ₁ - S ₂ | Ventral branches of Nn.
spinales sacrales |
| 15 | Branch of 3 to M. obliquus internus
abdominis | Th | Ventral branches of last thoracic
spinal nerve |
| 16 | Branch of 14 to M. retractor penis | | |

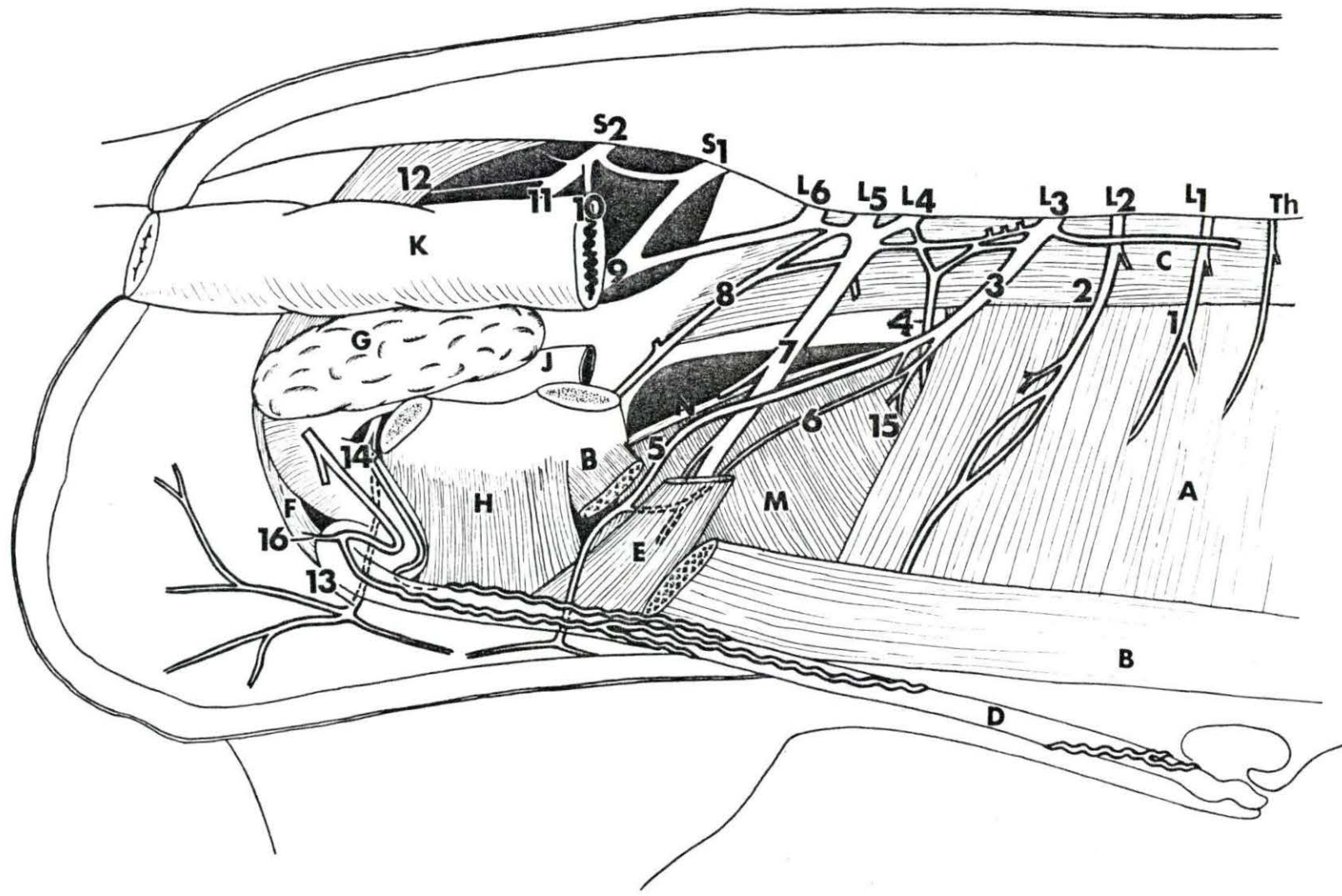


Figure 14. Gluteal region showing nerves before removal of the sacro-sciatic ligament, right side, lateral view

Specimen no. 10 ♂

- 1 N. ischiadicus
- 2 Communicating branch from N. ischiadicus to N. pudendus
- 3 N. gluteus caudalis
- 4 N. cutaneus femoris caudalis
- 5 Branch from 1 to Mm. biceps femoris and semitendinosus
- 6 Branch from 1 to distal part of M. biceps femoris
- 7 N. tibialis
- 8 N. cutaneus surae lateralis
- 9 N. fibularis (N. peroneus)
- 10 Branch from N. gluteus cranialis to M. tensor fasciae latae
- A M. gluteus medius (reflected)
- B M. semitendinosus
- C M. biceps femoris
- D M. vastus lateralis
- E M. tensor fasciae latae
- F M. gluteus profundus
- G Mm. gastrocnemius and soleus
- H Lig. sacrospinotuberale
- J Trochanter major
- K M. adductor

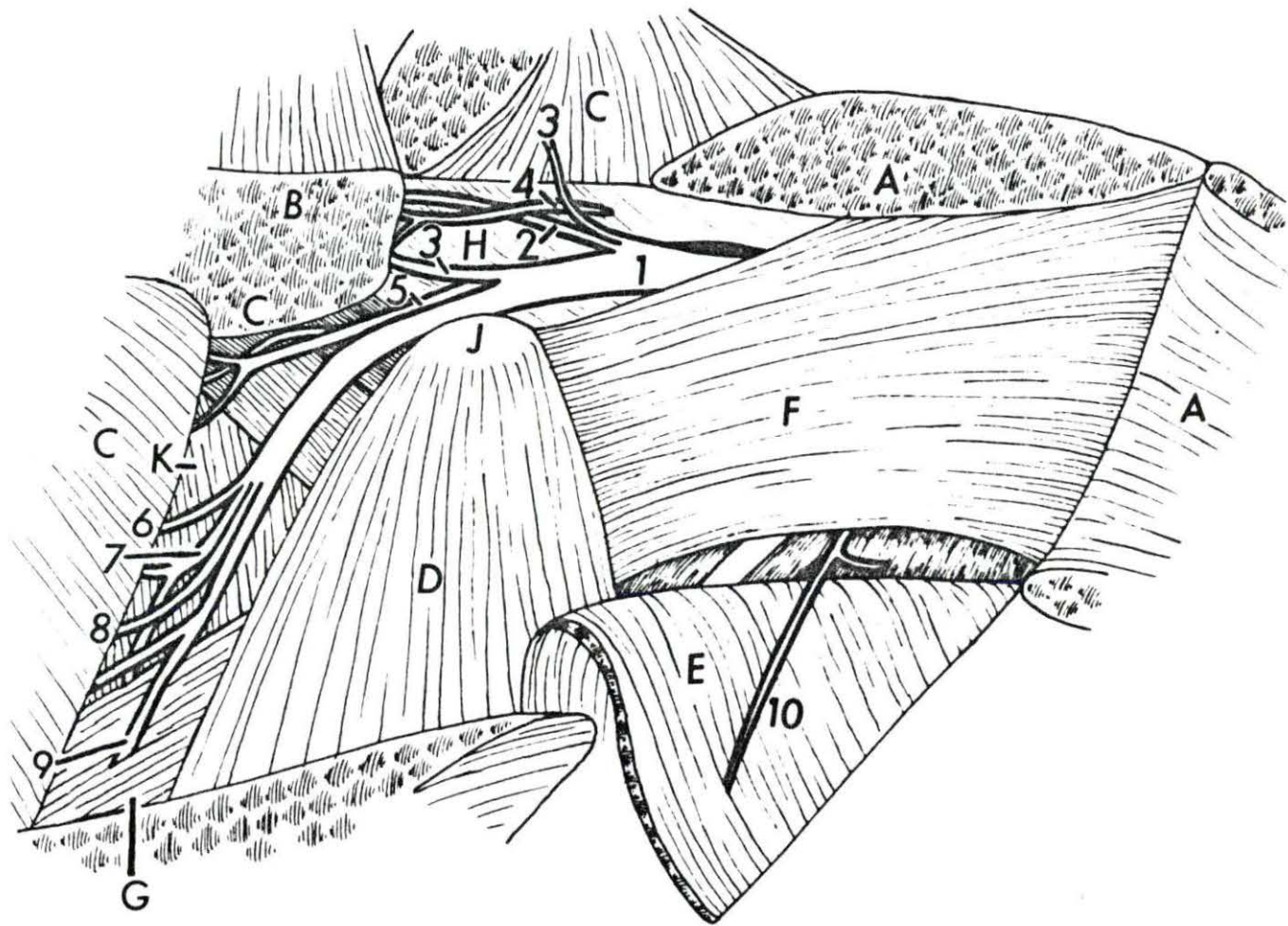


Figure 15. The gluteal region showing arrangement of nerves after removal of part of sacro-sciatic ligament, right side, lateral view

Specimen no. 10 ♂

- 1 N. ischiadicus
- 2 Communicating branch from N. ischiadicus to N. pudendus
- 3 N. gluteus caudalis
- 4 N. cutaneus femoris caudalis
- 5 Branch from 1 to Mm. biceps femoris, and semitendinosus
- 6 Branch of 1 to distal part of M. biceps femoris
- 7 N. tibialis
- 8 N. cutaneus surae lateralis
- 9 N. fibularis (N. peroneus)
- 10 Branch from N. gluteus cranialis to M. tensor fasciae latae
- 11 N. pudendus
- A M. gluteus medius reflected
- B M. semitendinosus
- C M. biceps femoris
- D M. vastus lateralis
- E M. tensor fasciae latae
- F M. gluteus profundus
- G Mm. gastrocnemius and soleus
- H Lig. sacrospinotuberale
- J Trochanter major
- K M. adductor

S₂ and S₃ Ventral branches of Nn. spinales sacrales

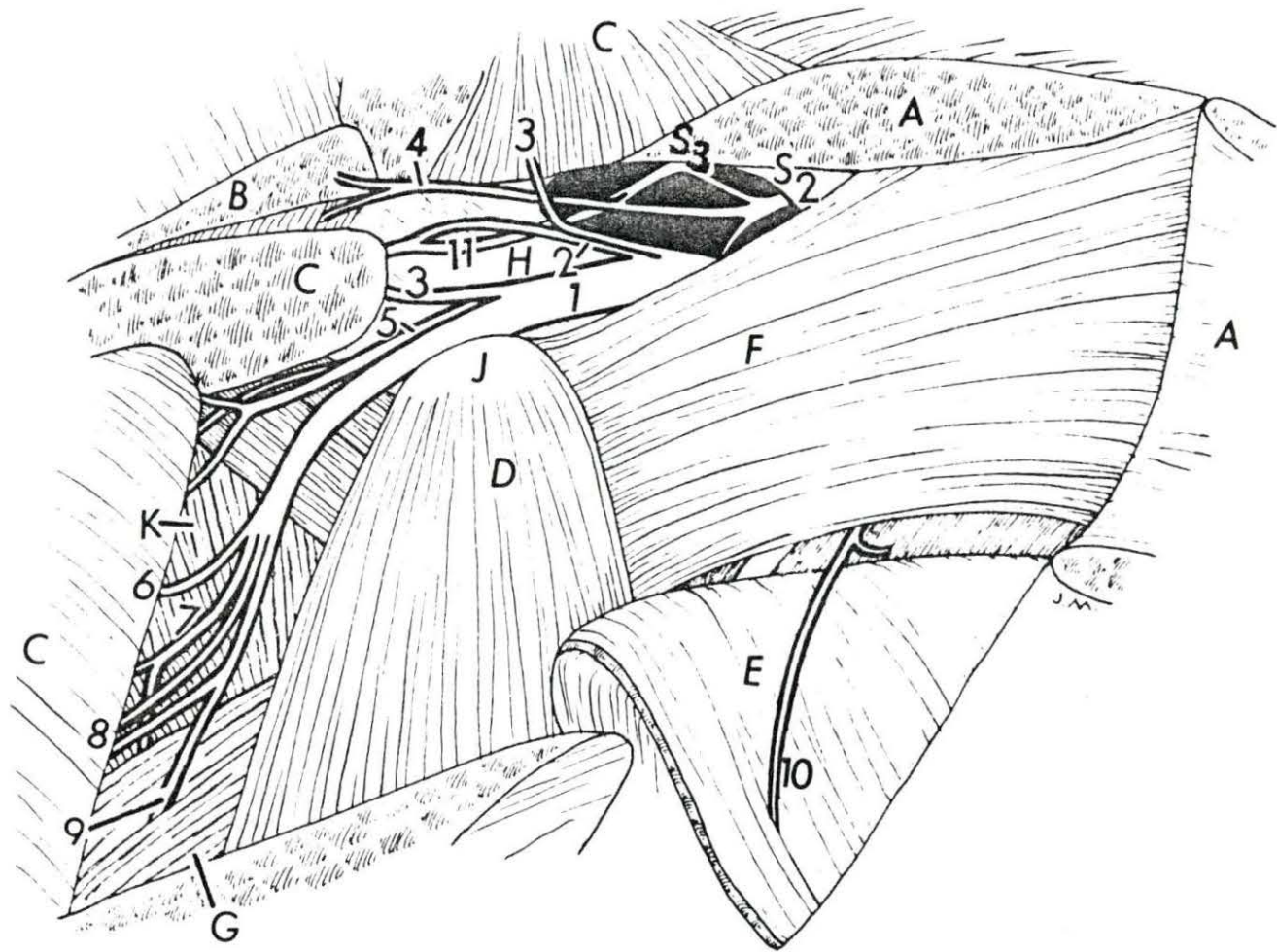


Figure 16. The lumbosacral plexus of the pig, right side,
ventral view

Specimen no. 10 ♂

- 1 N. iliohypogastricus
 - 2 N. ilioinguinalis
 - 3 Branch of N. genitalis to M. psoas major
 - 4 N. genitalis (N. spermaticus externus)
 - 5 N. cutaneus femoris lateralis
 - 6 N. femoralis
 - 7 N. obturatorius
 - 8 N. ischiadicus (here includes Nn. glutaeci)
 - 9 N. cutaneus femoris caudalis
 - 10 N. pudendus
 - 11 N. rectalis caudalis (N. haemorrhoidalis caudalis)
 - 12 Branch of 10 to urogenital tract and towards the pelvic plexus
 - 13 N. dorsalis penis
 - 14 N. splanchnicus pelvinus
- A rectum
B Urethra
- L₁ - L₆ Ventral branches of Nn. spinalis lumbales
S₁ - S₄ Ventral branches of Nn. spinalis sacrales
Th Ventral branch of last thoracic spinal nerve

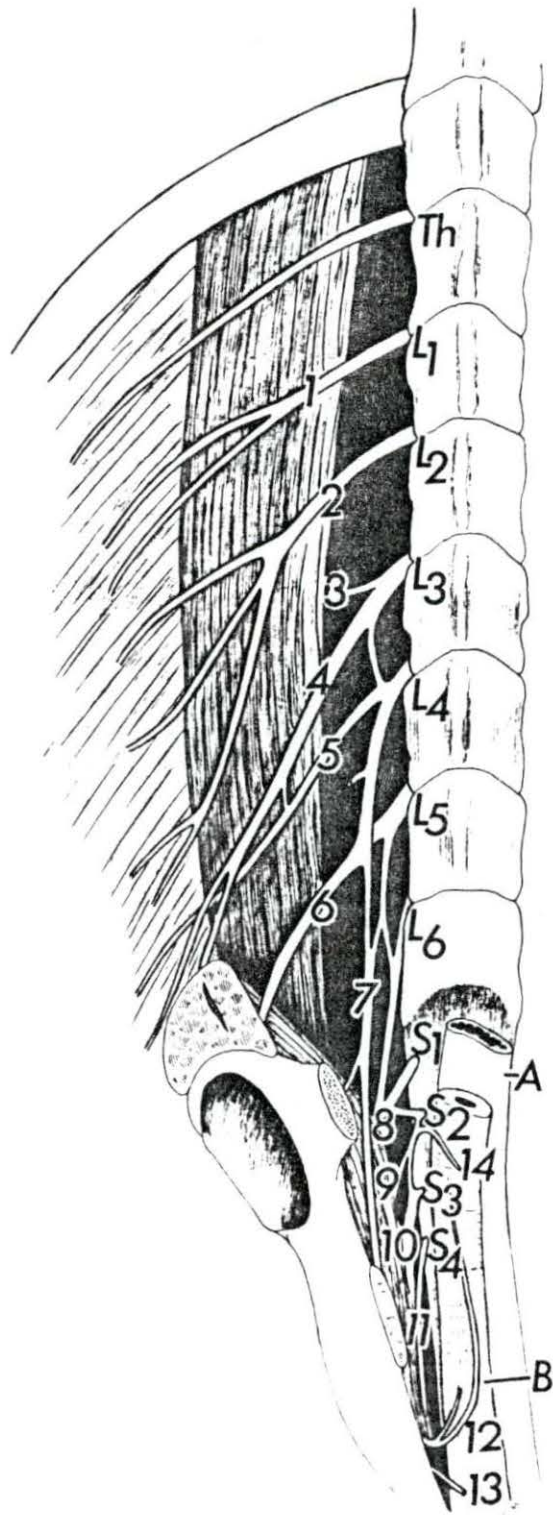


Figure 17. Somatic and autonomic nerves of the lumbar and pelvic regions, ventral view

Specimen no. 11 ♂

- 1 N. iliohypogastricus
- 2 N. ilioinguinalis
- 3 Branch of L₃ to Mm. psoas major et minor
- 4 N. genitalis (N. spermaticus externus)
- 5 N. cutaneus femoris lateralis
- 6 N. femoralis
- 7 N. obturatorius
- 8 N. ischiadicus
- 9 N. gluteus cranialis
- 10 Nn. splanchnici pelvini
- 11 Communicating branch from N. ischiadicus to N. pudendus
- 12 N. pudendus
- 13 Branch of l2 to M. coccygeus
- 14 and l4' N. splanchnicus major (thoracic splanchnic nerve)
- 15 Truncus sympathicus
- 16 Ganglia lumbalia (syst. sympathici)
- 17 Plexus aorticus abdominalis (systematis autonomici)
- 18 Cranial branch of plexus mesentericus caudalis
- 19 Caudal branch of plexus mesentericus caudalis
- 20 Ganglion mesentericus caudalis
- 21 N. hypogastricus (dexter et sinister) to plexus pelvinus
- 22 Ganglion sympathicum sacrale primum
- 23 N. perinealis superficialis from l2
- 24 Continuation of l2 as Nn. dorsalis penis and scrotalis medius
- 25 Ganglion et nervus testicularis at the base of A. testicularis (A. spermatica interna)
- L₁ - L₆ Ventral branches of Nn. spinales lumbales
- S₁ - S₄ Ventral branches of Nn. spinales sacrales
- Cy₁ Ventral branch of first coccygeal spinal nerve
- Th Ventral branches of last two thoracic spinal nerves

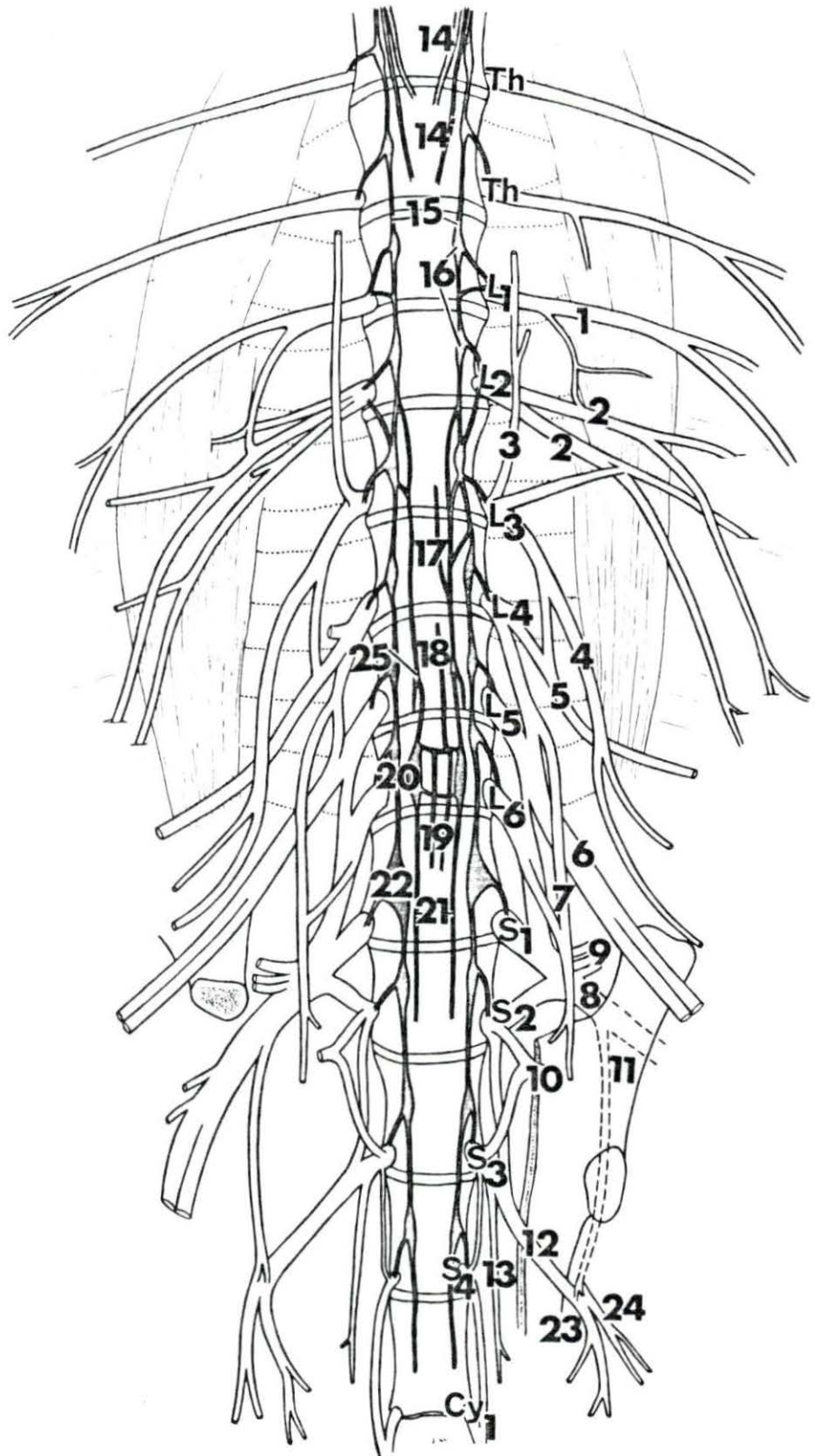


Figure 18. The sympathetic trunks and their relationship to the pudendal and pelvic nerves, lateral view

Specimen no. 11 ♂

- | | | | |
|----|--------------------------------------------------------------------------------------------------|-----------------------------------|---------------------------------------------|
| 1 | Nn. splanchnici major et minor (thoracic and abdominal splanchnic nerves) | 21 | N. deferentialis (syst. sympathici) from 11 |
| 2 | Trunci sympathici (dexter et sinister) | A | ureter |
| 3 | Plexus aorticus addominalis (syste. autonomici) | B | bladder |
| 4 | Cranial branch of plexus mesentericus caudalis (along cranial branch of A. mesenterica caudalis) | C | ductus deferens |
| 5 | N. testicularis (N. spermaticus internus) | D | glandula vesicula seminales |
| 6 | Ganglion for 5 | E | glandula bulbo-urethralis |
| 7 | Ganglion mesentericus caudalis | F | rectum |
| 8 | Caudal branch of plexus mesentericus caudalis (along caudal branch of A. mesenterica caudalis) | G | M. retractor penis |
| 9 | N. hypogastricus (dexter) | H | M. sphincter ani externus |
| 10 | Ganglion sympathicum sacrale primum | J | testis |
| 11 | N. splanchnicus pelvinus | K | M. cremaster externus |
| 12 | N. pudendus | M | M. ischiocavernosus penis |
| 13 | Communicating branch from N. ischiadicus to N. pudendus | N | penis |
| 14 | Branches from pelvic plexus to M. retractor penis and to rectum | O | preputial diverticulum |
| 15 | Common nerve trunk for Nn. perinei | L ₁ - L ₆ | Lumbar vertebrae |
| 16 | Branch of 12 to urogenital tract | S ₁ - S ₄ | Sacral vertebrae |
| 17 | Branch of 15 - N. perinealis superficialis (N. scrotalis caudalis) | Cy ₁ - Cy ₂ | Coccygeal vertebrae |
| 18 | N. scrotalis medius from 12 | Th | Last two thoracic vertebrae |
| 19 | N. dorsalis penis (continuation of 12) | | |
| 20 | Branch of 19 to distal part of M. retractor penis | | |

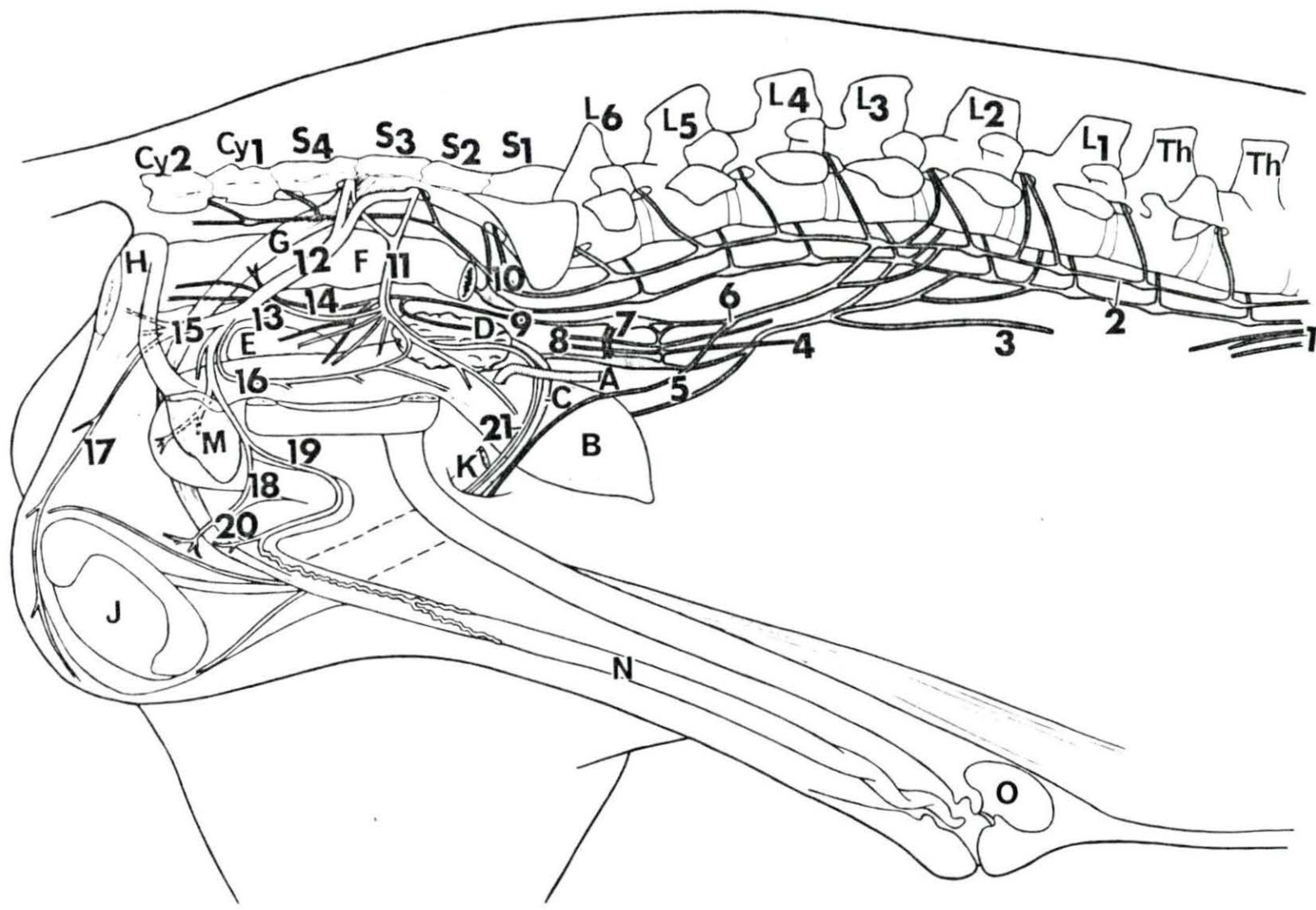
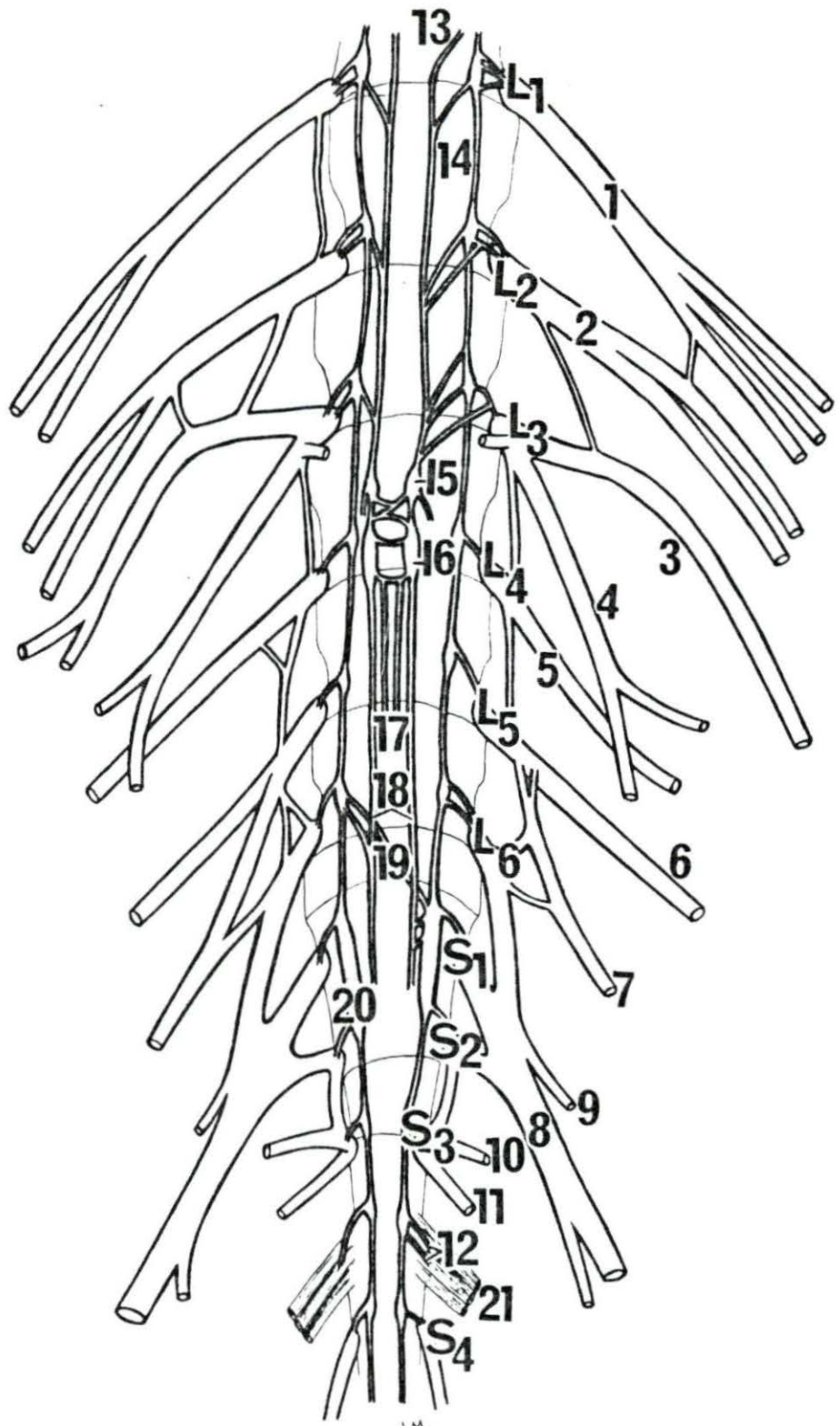


Figure 19. Somatic and autonomic nerves of the lumbar and pelvic regions, ventral view

Specimen no. 12 ♂

- 1 N. iliohypogastricus
 - 2 N. ilioinguinalis
 - 3 Branch from L₂ and L₃ to M. cremaster externus
 - 4 N. genitalis (N. spermaticus externus)
 - 5 N. cutaneus femoris lateralis
 - 6 N. femoralis
 - 7 N. obturatorius
 - 8 N. ischiadicus
 - 9 N. gluteus cranialis
 - 10 N. splanchnicus pelvinus
 - 11 N. pudendus
 - 12 Branches from Truncus sympathicus to M. retractor penis
 - 13 Plexus aorticus abdominalis (syst. autonomici)
 - 14 Truncus sympathicus (sinister)
 - 15 Ganglion testicularis at the base of A. testicularis (A. spermatica interna)
 - 16 Ganglion mesentericus caudalis
 - 17 Caudal branch of plexus mesentericus caudalis (along caudal branch of A. mesenterica caudalis)
 - 18 Nn. hypogastrici to plexus pelvini
 - 19 Communication between last lumbar ganglion of right side and first two fused sacral ganglia of the left side
 - 20 First two fused sacral ganglia of the right side
 - 21 M. retractor penis
- L₁ - L₆ Ventral branches of Nn. spinales lumbales
S₁ - S₄ Ventral branches of Nn. spinales sacrales



J.M.

Figure 20. Somatic and autonomic nerves of the lumbar and pelvic regions,
ventral view

Specimen no. 12 ♂

- | | | | |
|----|----------------------------------------------------------------------------|-----------------------------------|-------------------------------------------|
| 1 | Ganglion testicularis | A | Aorta |
| 2 | Ganglion mesentericus caudalis | B | A. and V. iliaca externa |
| 3 | N. testicularis (N. spermaticus internus) | C | Ureter |
| 4 | N. hypogastricus | D | Bladder |
| 5 | Rami splanchnici sacrales joining 4 | E | Vas deferens |
| 6 | N. splanchnicus pelvinus (severed from S ₂ and S ₃) | F. | As. umbilicalis et vesicalis cranialis |
| 7 | Plexus vesicalis | G | Rectum |
| 8 | Branches from Truncus sympathicus to M. retractor penis | H | M. cremaster externus |
| 9 | Plexus pelvinus | J | M. retractor penis |
| 10 | Plexus rectalis to terminal part of rectum and M. sphincter ani internus | K | Glandula vesicula seminalis |
| 11 | Branch from N. pudendus to urogenital tract | M | Urethra and M. urethralis |
| 12 | Branch from L ₂ and L ₃ to M. cremaster externus | N | M. obliquus internus abdominis |
| 13 | N. genitalis (N. spermaticus externus) | O | M. rectus abdominis |
| 14 | N. cutaneus femoris lateralis | P | Ln. inguinalis superficialis |
| 15 | N. obturatorius | Q | A. and V. pudenda externa |
| 16 | N. femoralis | R | A. urethrogenitalis |
| 17 | Truncus sympathicus | T | A. circumflexa ilium profunda |
| 18 | N. ischiadicus | U | Glandula bulbourethralis |
| 19 | N. pudendus | V | M. quadratus lumborum |
| 20 | Branches of L ₂ and L ₃ to M. cremaster externus | W | A. testicularis (A. spermatic interna) |
| 21 | Branch of L ₃ to M. psoas major | X | A. colica sinister |
| | | L ₃ and L ₄ | Ventral branches of Nn. spinales lumbales |
| | | S ₁ and S ₃ | Ventral branches of Nn. spinales sacrales |

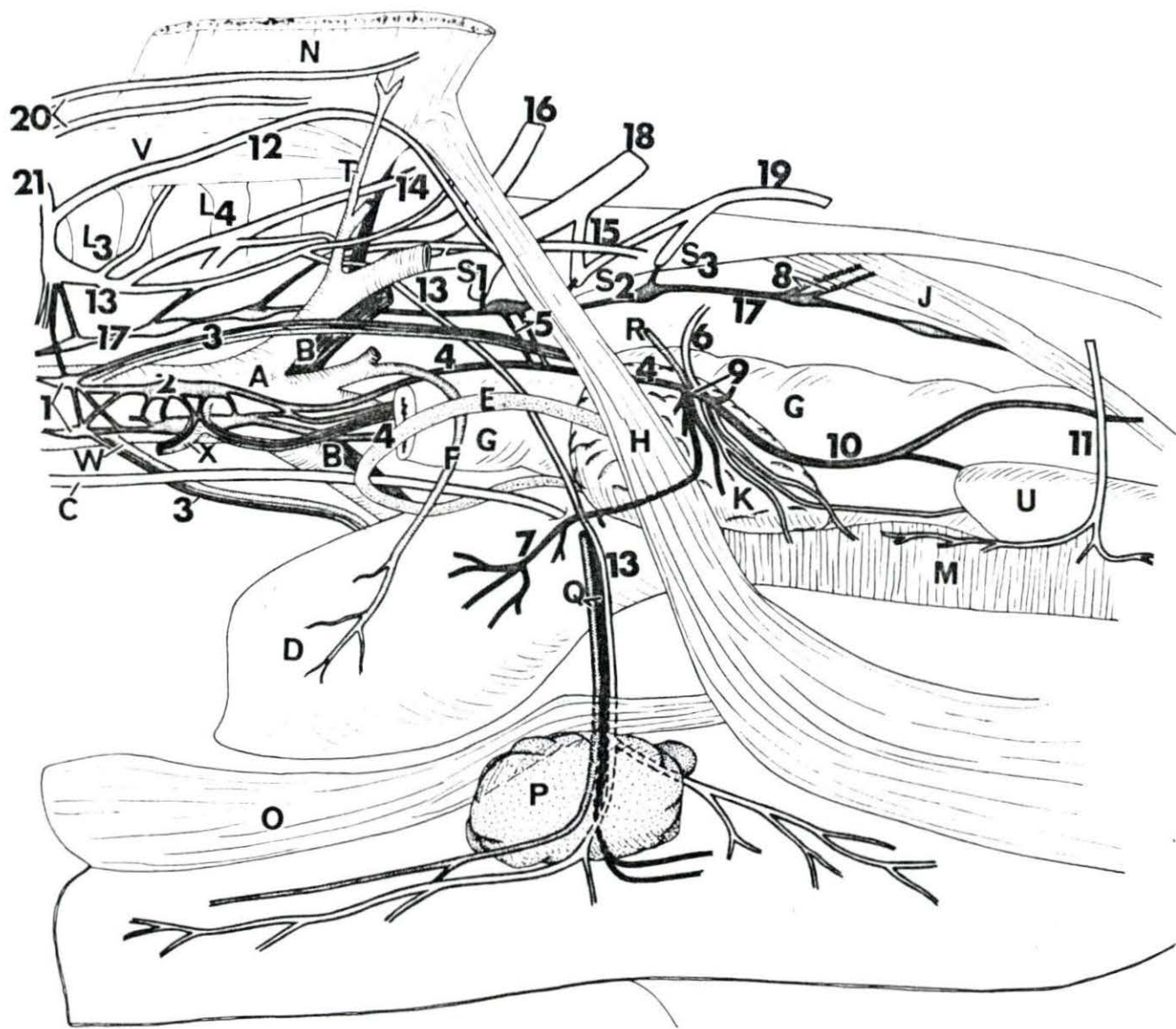


Figure 21. Somatic and autonomic nerves of the lumbar and pelvic regions, ventral view

Specimen no. 13 ♂

- 1 N. iliohypogastricus
- 2 N. ilioinguinalis
- 3 Branch from 2 to M. cremaster externus
- 4 Branch from 3 to M. psoas major
- 5 N. genitalis (N. spermaticus externus)
- 6 N. cutaneus femoris lateralis
- 7 N. femoralis
- 8 N. obturatorius
- 9 N. gluteus cranialis
- 10 N. ischiadicus
- 11 Communicating branch from N. ischiadicus to N. pudendus
- 12 N. pudendus
- 13 Branch from S₃ to M. coccygeus
- 14 N. splanchnicus pelvinus
- 15 N. splanchnicus major (thoracic splanchnic nerve)
- 16 Ganglion coeliacus
- 17 Ganglion mesentericus cranialis
- 18 Ganglion et plexus renalis
- 19 Ganglion testicularis at base of A. testicularis (A. spermatica interna)
- 20 Ganglion mesentericus caudalis
- 21 N. hypogastricus
- 22 Caudal branch of plexus mesentericus caudalis (along caudal branch of A. mesenterica caudalis)
- 23 Branch from Truncus sympathicus to M. retractor penis
- 24 N. splanchnicus minor (lumbar splanchnic nerve)
- A Aorta abdominalis
- B Vena cava caudalis
- C M. retractor penis
- D A. phrenico-abdominalis
- E A. renalis
- L₁ - L₆ Ventral branches of Nn. spinales lumbales
- S₁ - S₄ Ventral branches of Nn. spinales sacrales
- Cy₁ Ventral branch of first coccygeal nerve
- Th Last thoracic spinal nerve

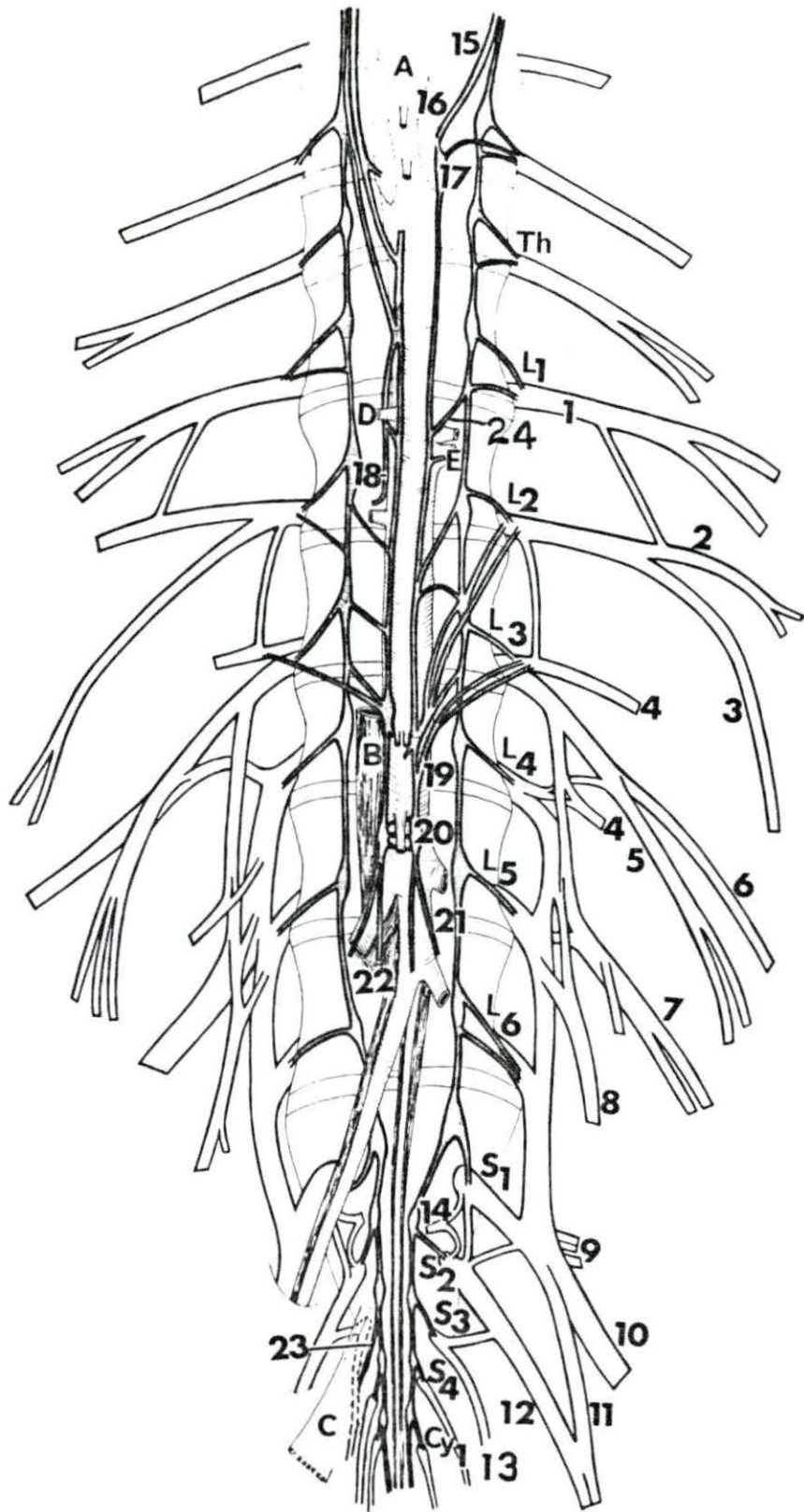


Figure 22. Somatic and autonomic nerves of the pelvic and coccygeal regions, ventral view

Specimen no. 14 ♀

- 1 N. femoralis
 - 2 N. obturatorius
 - 3 N. ischiadicus
 - 4 N. splanchnicus pelvinus
 - 5 N. cutaneus femoris caudalis
 - 6 N. pudendus
 - 7 Communicating branch from N. ischiadicus to N. pudendus
 - 8 Branch from 6 to M. coccygeus
 - 9 Continuation of 6 as Nn. clitoridis and mammarius caudalis
 - 10 Branch of 6 as Nn. perinei
 - 11 Ganglion paravertebrale accessorius
 - 12 Plexus formed by the right and left sympathetic trunks at the third sacral ganglia
 - 13 N. glutaesus caudalis
 - 14 N. rectalis caudalis (N. haemorrhoidalis caudalis)
 - 15 Branches from S₃ to M. sphincter ani externus (N. perinealis profundus)
- A M. quadratus lumborum
B M. transversus abdominis
C Os ilium (cut)
- L₄ - L₆ Ventral branches of Nn. spinales lumbales
S₁ - S₄ Ventral branches of Nn. spinales sacrales
Cy₁ - Cy₂ Ventral branches of Nn. coccygei

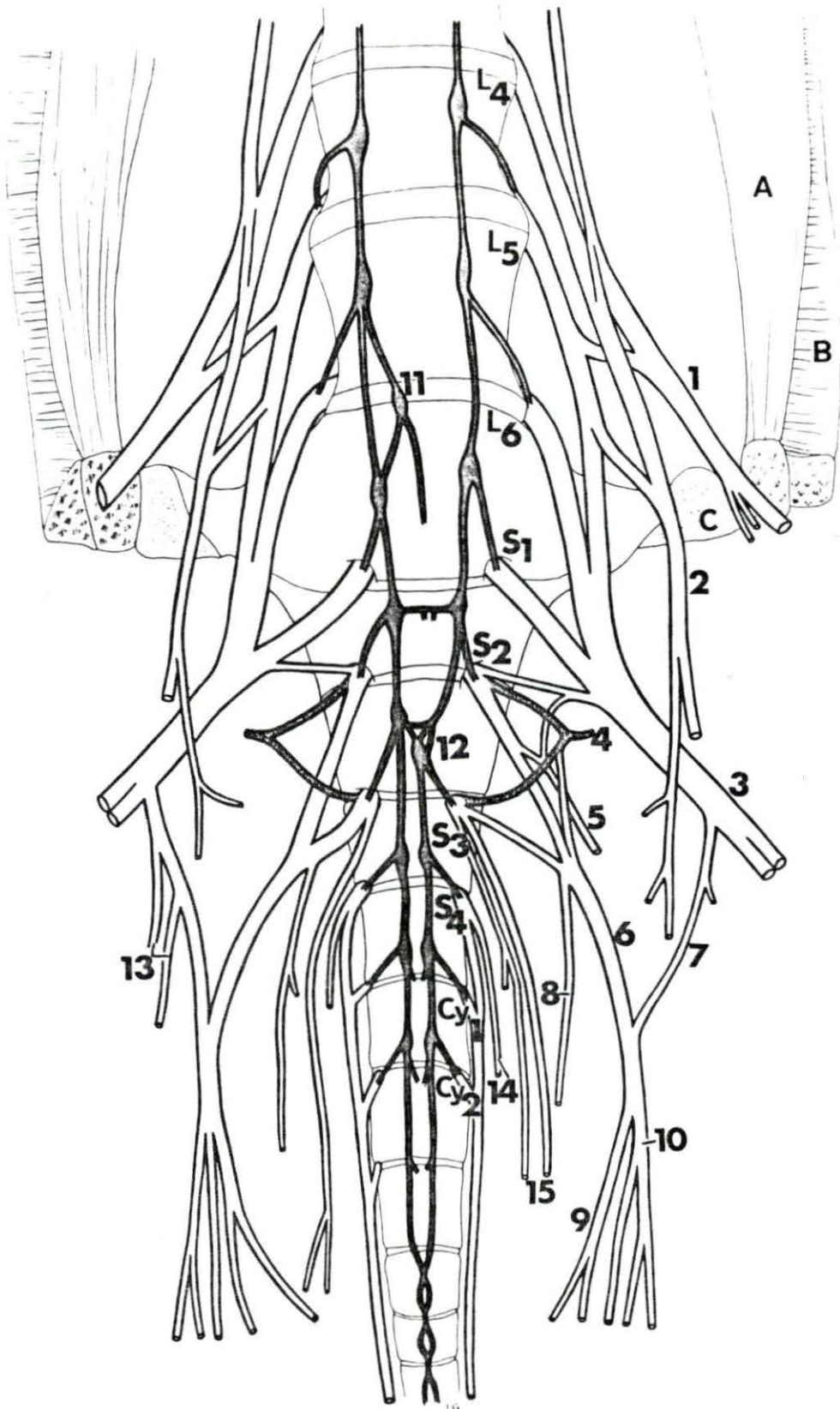


Figure 23. Disposition of the sympathetic trunks and collateral ganglia in the lumbar region, ventral view

Specimen no. 15 ♀

- 1 Truncus vagalis dorsalis (dorsal esophageal branch of vagus nerve)
 - 2 Nn. splanchnici major (thoracic splanchnic nerves), including those to the Ganglia coeliaco-mesentericus and plexus adrenalis
 - 3 Nn. splanchnici lumbales
 - 4 Ganglia coeliaco-mesenterici
 - 5 Ganglion renalis
 - 6 Plexus renalis
 - 7 Ganglion mesentericus caudalis
 - 8 N. hypogastricus
 - 9 N. ovaricus (N. utero-ovaricus)
 - 10 Cranial branch of plexus mesentericus caudalis (along cranial branch of A. mesenterica caudalis)
 - 11 Caudal branch of plexus mesentericus caudalis (along caudal branch of A. mesenterica caudalis)
- A M. psoas major
B Aorta
C A. coelica
D A. mesenterica cranialis
E A. renalis
F A. and V. phrenico-abdominalis
G Arteries to Glandula adrenalis
H A. mesenterica caudalis
J A. ovarica (A. utero-ovarica)
K A. iliaca externa
L₁ - L₆ Ventral branches of Nn. spinales lumbales
Th Last thoracic spinal nerve

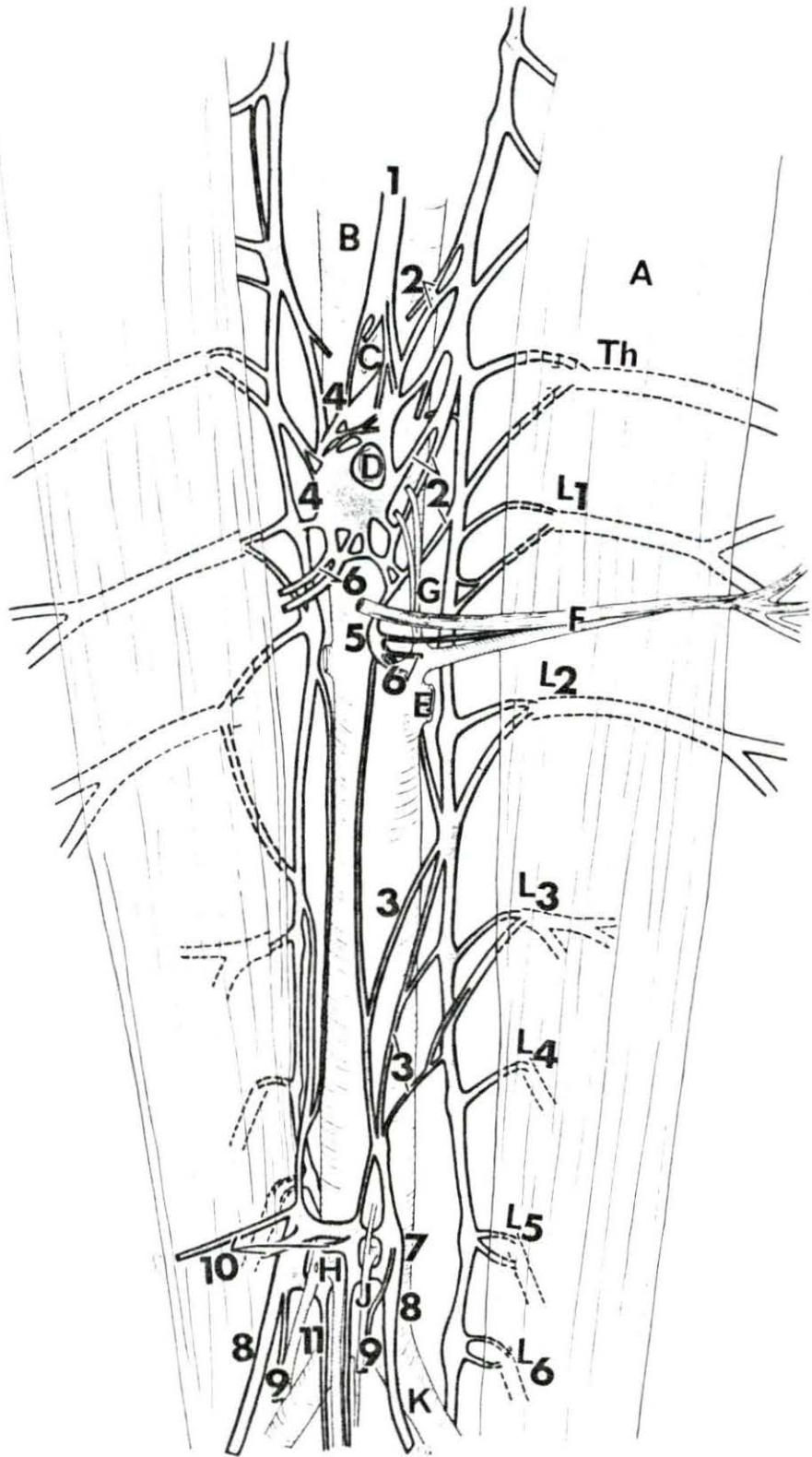


Figure 24. The sacro-coccygeal part of the sympathetic trunks, ventral view

Specimen no. 15 ♀

- 1 Truncus sympathicus (Pars sacralis)
- 2 Truncus sympathicus (Pars coccygealis)
- B Terminal part of the Aorta abdominalis
- K A. iliaca externa
- M A. iliaca interna
- N A. sacralis mediana
- O A. coccygea mediana
- S₁ First sacral vertebra
- Cy₁ First coccygeal vertebra
- Cy₄ Fourth coccygeal vertebra

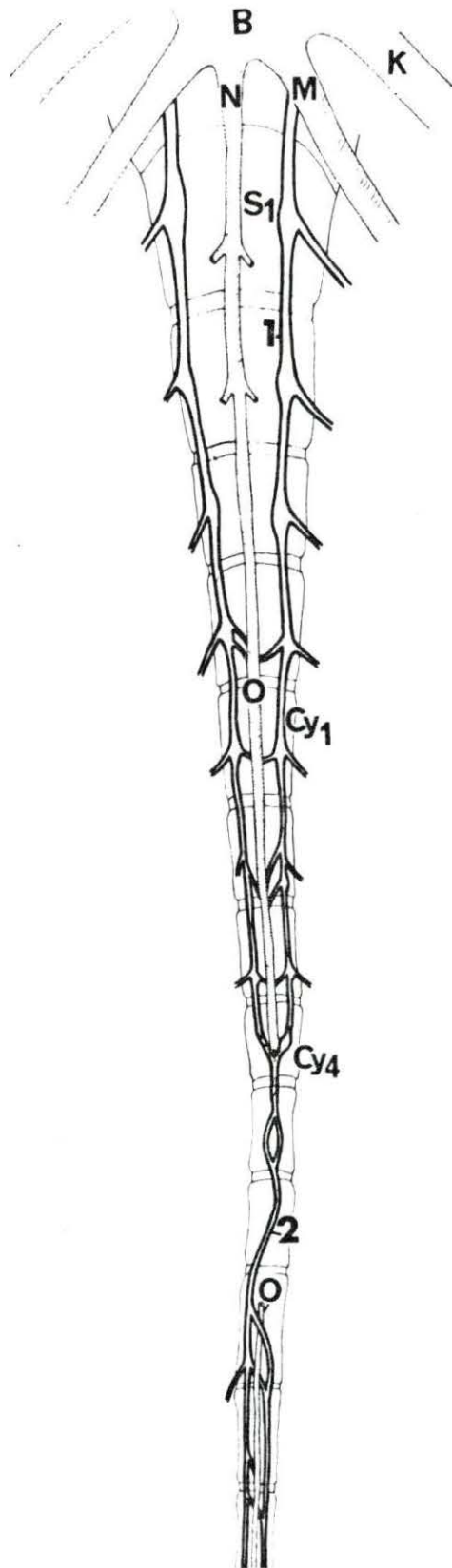
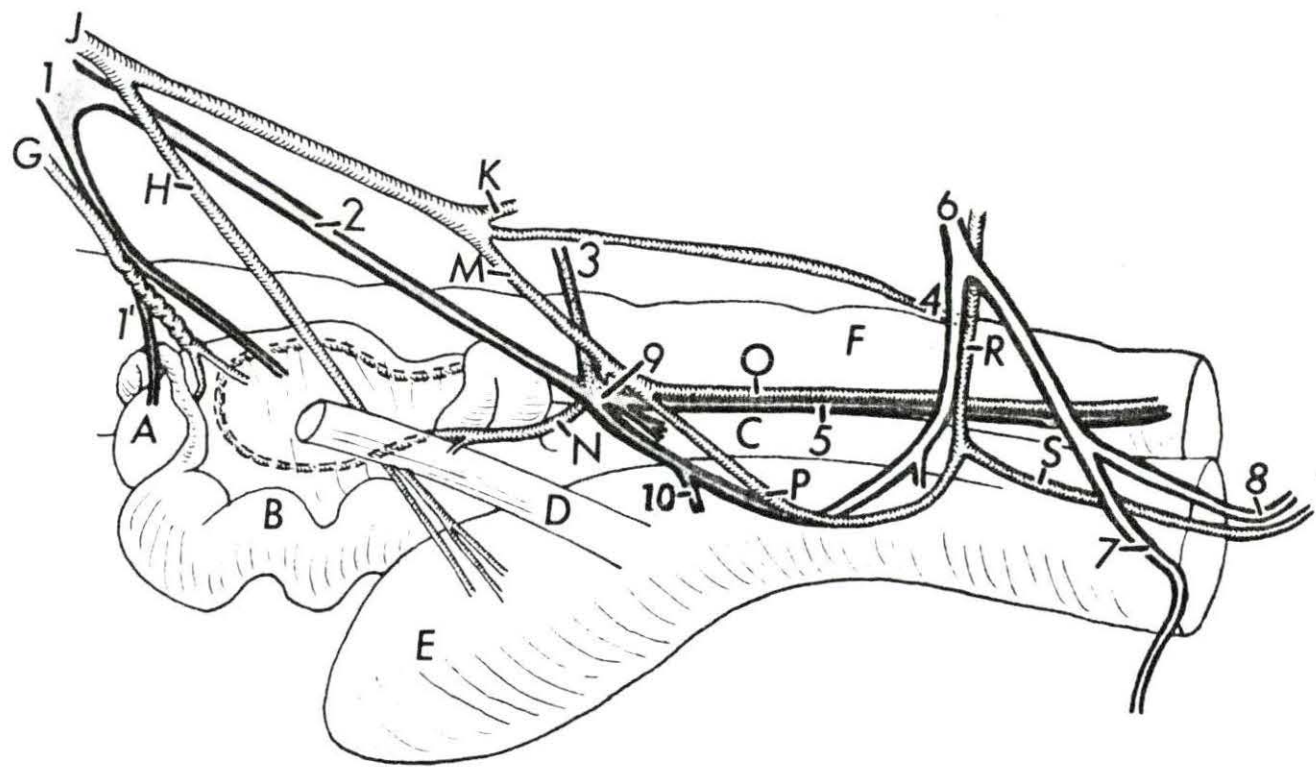


Figure 25. Disposition of the pelvic Plexus left view

Specimen no. 15 ♀

- 1 Ganglion mesentericus caudalis
- 1' N. ovaricus (N. utero-ovaricus)
- 2 N. hypogastricus
- 3 N. splanchnicus pelvinus
- 4 Branch from N. pudendus toward Plexus pelvinus
- 5 Plexus rectalis (Plexus haemorrhoidalis)
- 6 N. pudendus
- 7 N. mammarius caudalis
- 8 N. clitoridis from 6
- 9 Plexus pelvinus
- 10 Plexus vesicalis
- A Ovary
- B Uterus
- C Vagina
- D Ureter
- E Bladder
- F Rectum
- G A. ovarica (A. utero-ovarica)
- H A. umbilicalis
- J A. iliaca interna
- K A. glutaeta cranialis
- M A. urogenitalis
- N Ramus uterinus of A. urogenitalis
- O A. rectalis media (A. haemorrhoidalis media)
- P Anastomosis between A. urogenitalis and A. pudenda interna
- R A. pudenda interna
- S A. clitoridis



186a

APPENDIX C

Plate 1. The lumbosacral plexus of the pig, left side, lateral view

Specimen no. 3

- 1 N. iliohypogastricus
- 2,2' N. ilioinguinalis and its cutaneous branches
- 3 Branch of L₂ and L₃ to M. obliquus internus abdominis
- 4 Branch of L₃ to M. psoas major
- 5 N. genitalis (N. spermaticus externus)
- 6,6' N. cutaneus femoris lateralis and its continuation
- 7 N. femoralis, and beside it caudally, N. obturatorius
- 8 Ventral branch of L₆ spinal nerve joining S₁
- 9 N. gluteus cranialis
- 10 N. gluteus caudalis (had fibers of N. cutaneus femoris caudalis in it)
- 10' N. gluteus caudalis
- 11 N. ischiadicus
- 12 N. pudendus
- 13 Communicating branch from N. ischiadicus to N. pudendus
- 14 N. perinealis profundus
- 15 N. rectalis caudalis (N. haemorrhoidalis caudalis)
- 16 N. perinealis profundus (N. perinealis medius)
- 17 Branch of S₄ to Nn. coccygei
- 18 Branch from N. ischiadicus to proximal part of M. biceps femoris
- 19 N. fibularis
- 20 N. tibialis
- 21 N. cutaneus surae lateralis (caudalis)
- 22 Dorsal branch of L₇ spinal nerve


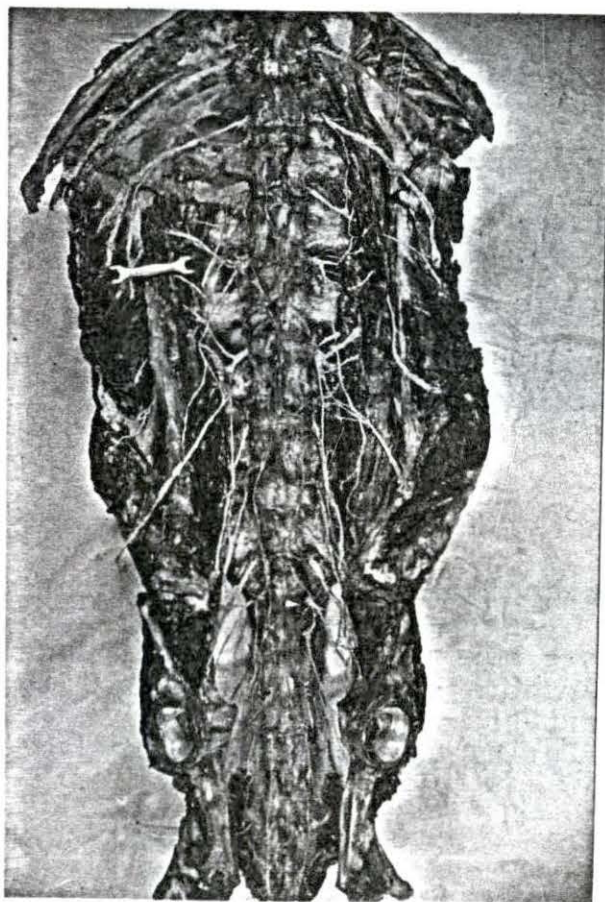
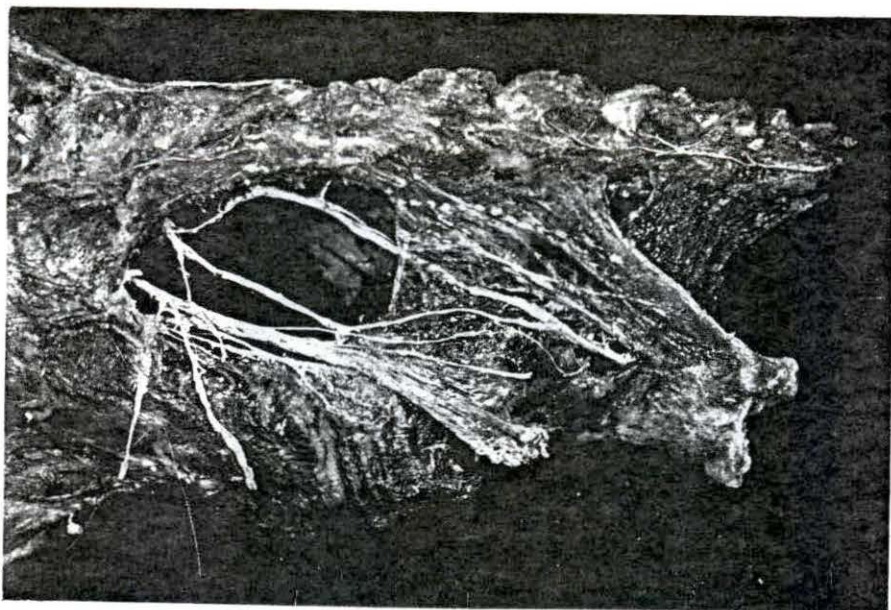


Plate 2: The gluteal and ventral views of the lumbosacral plexus.

Specimen no. 4 ♀

Top: The gluteal region showing the sacral part of the lumbosacral plexus. Dotted line is course of N. cutaneus femoris caudalis.

Bottom: Ventral branches of the lumbar and sacral spinal nerves and the sympathetic trunks ventral view specimen no. 4. Same as Figure 4.



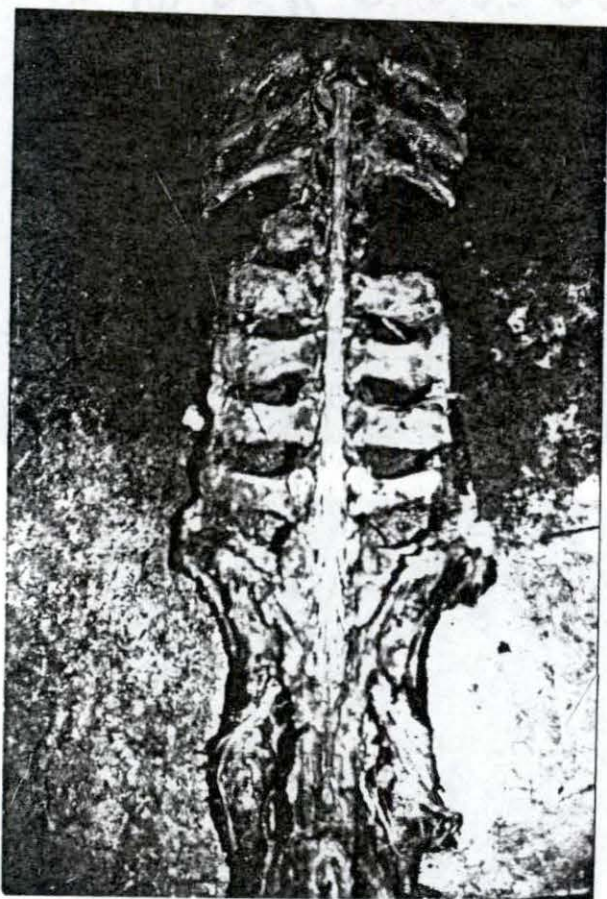


Plate 3. Spinal cord dissected out to show the different segments of spinal nerve origins. The last pair of openings bordering transverse process of the lumbar vertebra caudally is cranial to the sixth lumbar vertebra which is closely adhered to the sacrum. Dorsal view specimen no. 5 ♀.

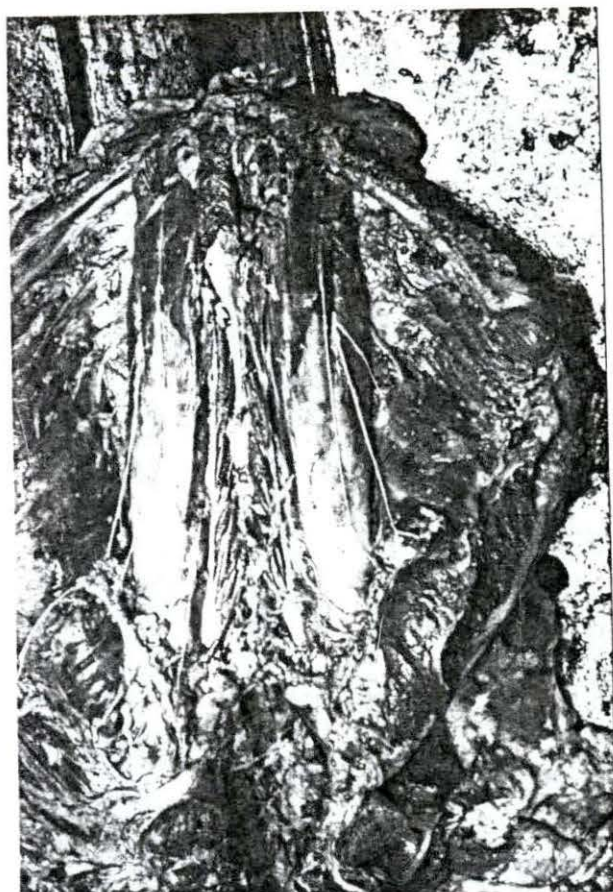


Plate 4. Superficial view of the arrangement of the ventral branches of the lumbar spinal nerves in relation to Mm. psoas major and minor in situ ventral view specimen no. 6 ♀. Same as Figure 7. Note the branches of the L₂ spinal nerve emerging from the proximal third of M. psoas major.

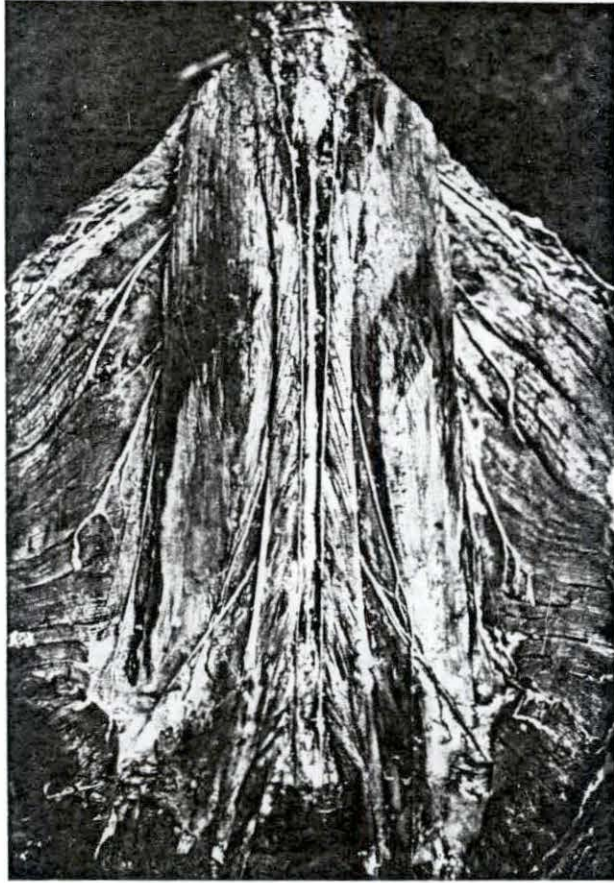


Plate 5. Another mode of the arrangement of the ventral branches of lumbar spinal nerves in relation to Mm. psoas major and minor. Ventral view specimen no. 8 ♀. Same as Figure 11. It is the most common arrangement of the nerves in the lumbar region. Note the emergence of the L₂ spinal nerves from the lateral border of each M. psoas major.

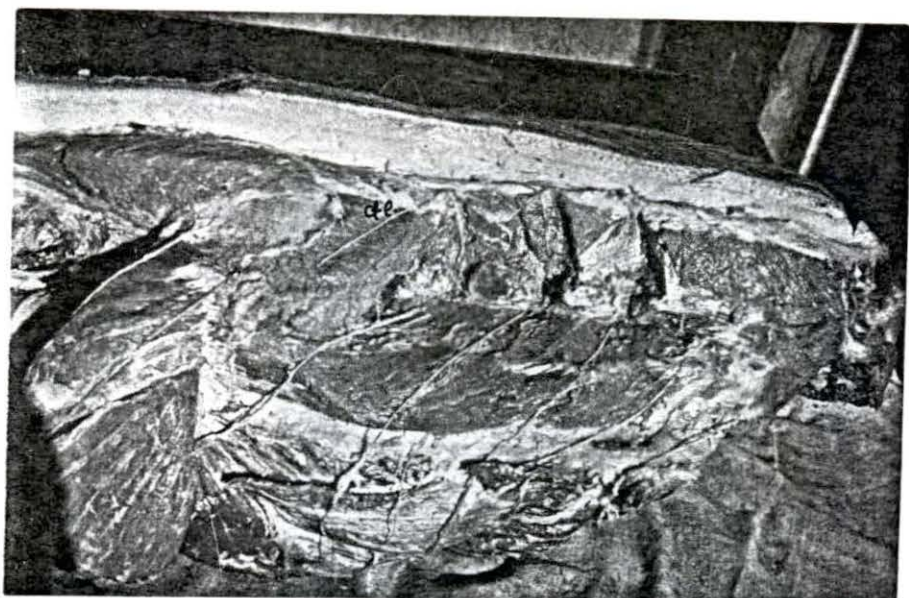


Plate 6. The dorsal branches of the lumbar spinal nerves specimen no. 7 ♀. Note how the medial branches course under the articular processes emerge at the summit of spinous processes and then pass latero-caudally under the skin, (d.l.) dorso-lateral cutaneus branch. See Figure 6.

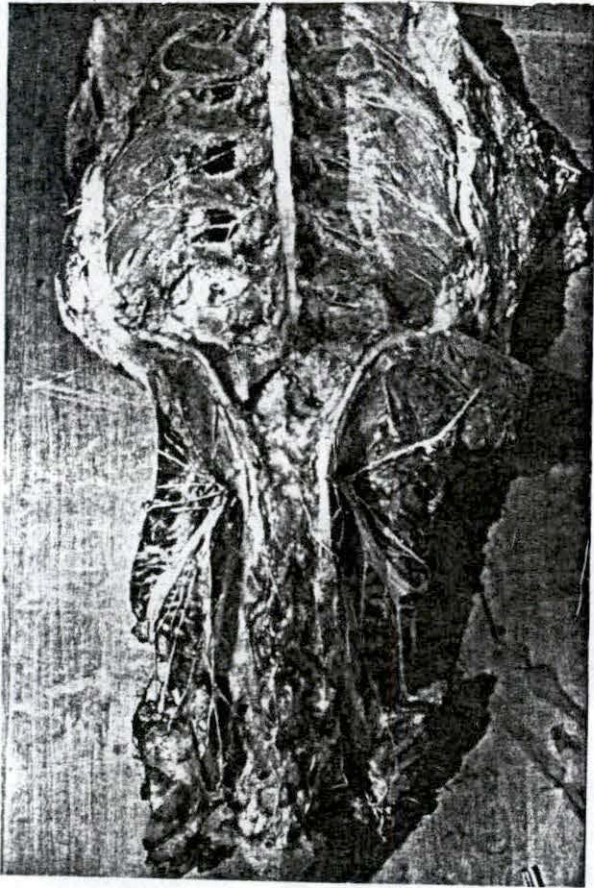


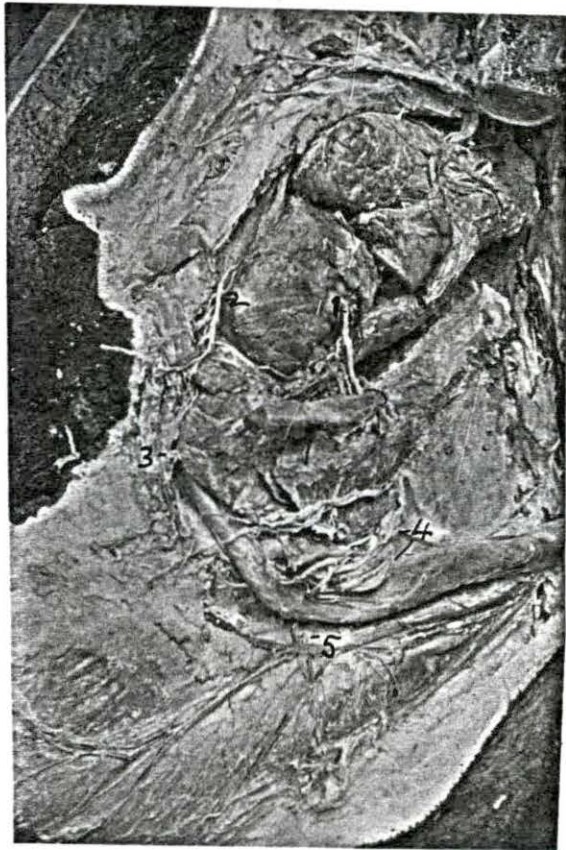
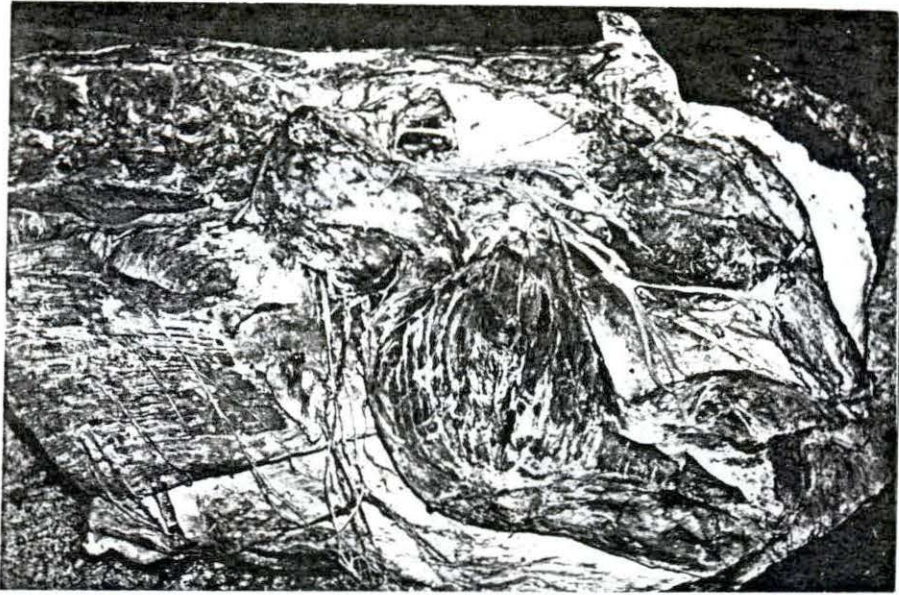
Plate 7. The lumbar, gluteal and ischio-anal fossa, dorsal-lateral view specimen no. 80. Note the dorsal branches in the lumbar and sacral regions. Also note the nerves in the ischio-anal fossa as shown in Figure 10.

Plate 8: Lateral and medial aspects of the lumbar
sacral and femoral regions

Specimen no. 9 ♂

Top: Paralumbar, gluteal and femoral regions
left side lateral view specimen no. 9
6. Same as Figure 12. Note the branches
of N. cutaneus femoris lateralis.

Bottom: Pelvic cavity medial aspect of left
half of scrotum showing the N. pudendus
(1) emerging under accessory sex glands;
Nn. perineales profunda (2); N.
scrotalis caudalis (3); Nn. dorsalis
penis (4); N. scrotalis medius (5).



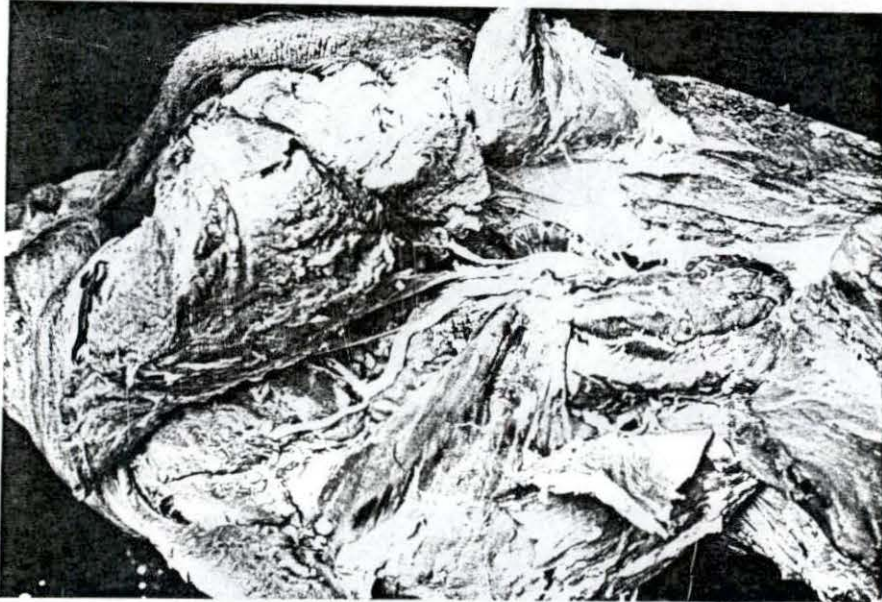


Plate 9. Gluteal and lateral femoral region showing Nn. ischiadicus, gluteus cranialis gluteus caudalis, tibialis, fibularis and cutaneus femoris caudalis, right side lateral view. Specimen no. 10 (8)
Male castrated - same as Figures 14 and 15.

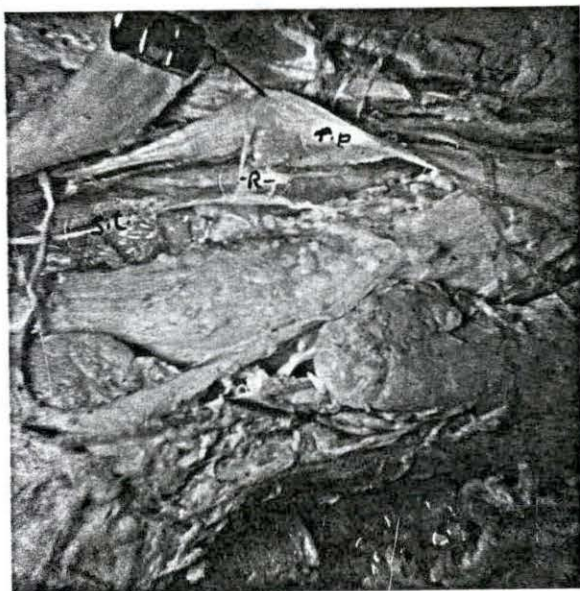

Plate 10. Opened pelvis showing sympathetic trunk (s.t) with two rami to the vertebral end of M. retractor penis r.p at R. Specimen no. 12 ♂. See Figure 19: 12.



Plate 11. Somatic and autonomic nerves of the lumbar and pelvic regions - left side, ventro-lateral view. Observe the Truncus sympathicus (1), Nn. splanchnici lumbales (2) and Nn. intermesenterici (3) stretching along the Aorta abdominalis. (Same as Figure 21).

Plate 12. Somatic and autonomic nerves of the pelvic
and coccygeal regions ventral view.
Specimen no. 14 ♀. Same as Figure 22 in
labelling.

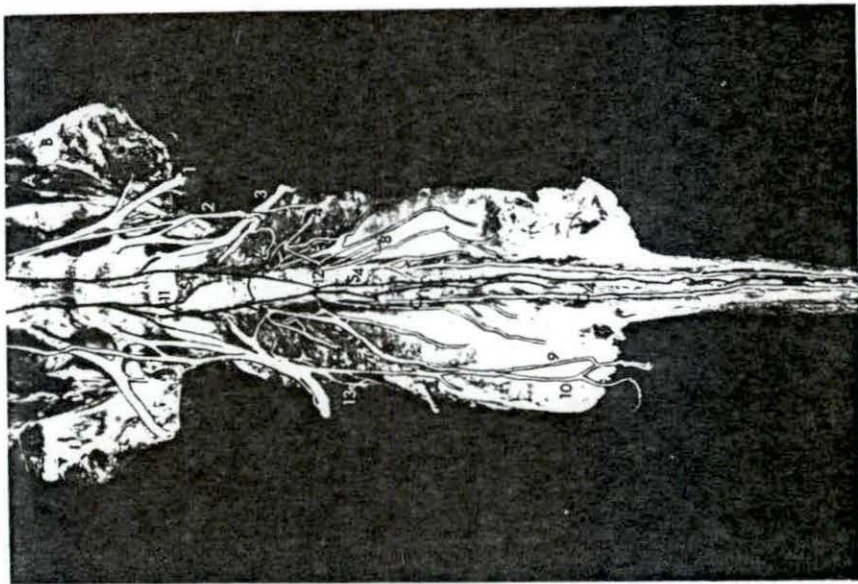
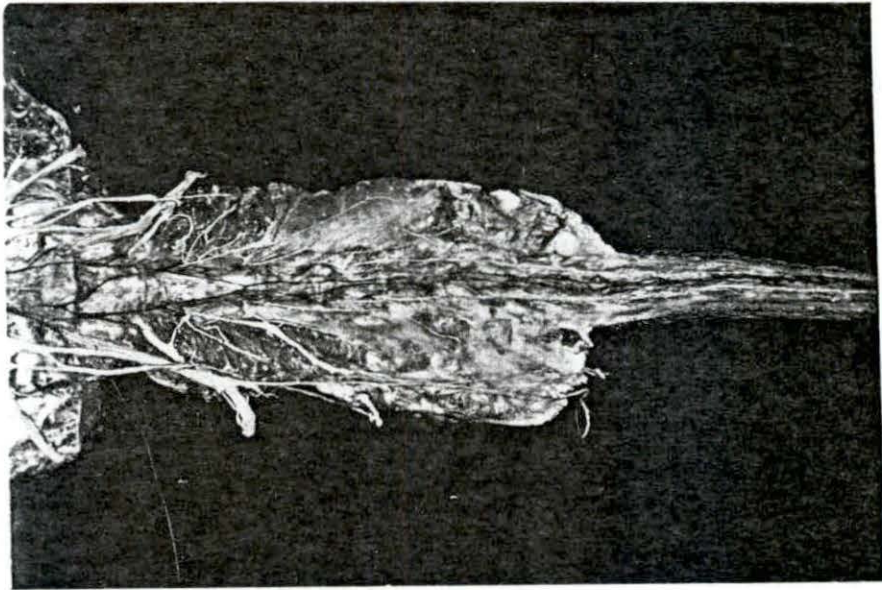


Plate 13. Disposition of the sympathetic trunks and collateral ganglia in the lumbar and sacro-coccygeal regions ventral view. Specimen 15 ♀. Labelled as Figures 23 and 24.





Plate 14a. Disposition of the sympathetic trunk, thoracic and lumbar splanchnic nerves and rami communicantes, left side, ventral view. Specimen no. 15 ♀. As Figure 23.

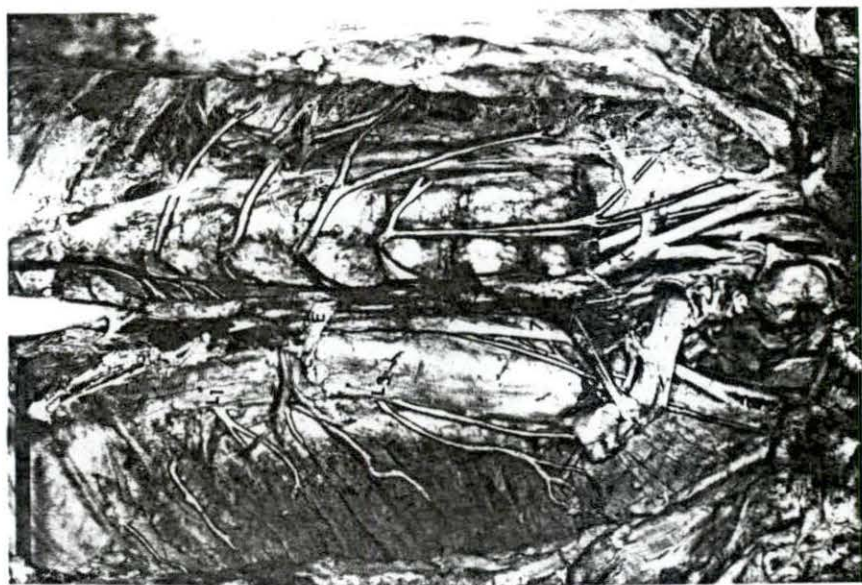
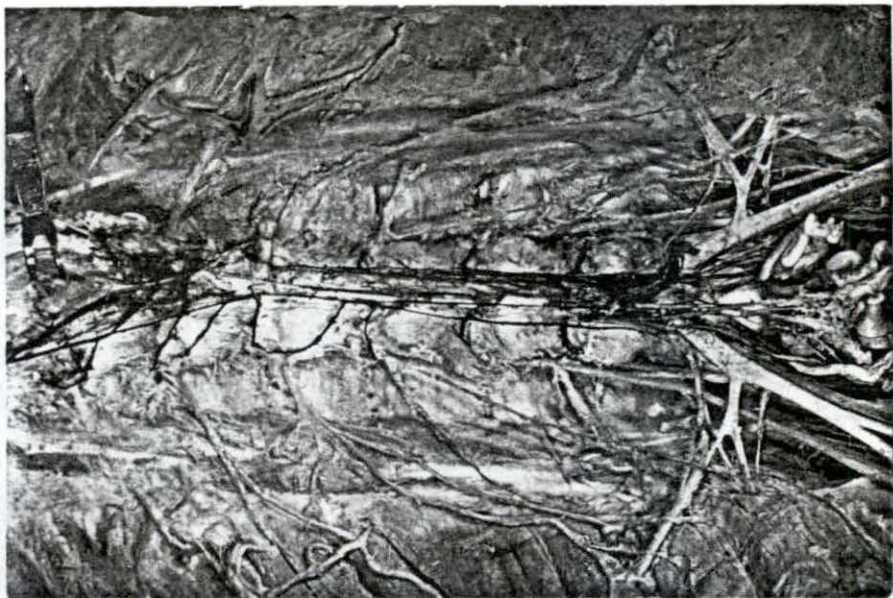



Plate 14b. Disposition of the sympathetic trunk, thoracic and lumbar splanchnic nerves and Rami communicantes, right side, ventral view. Specimen no. 15 ♀ as Figure 23.



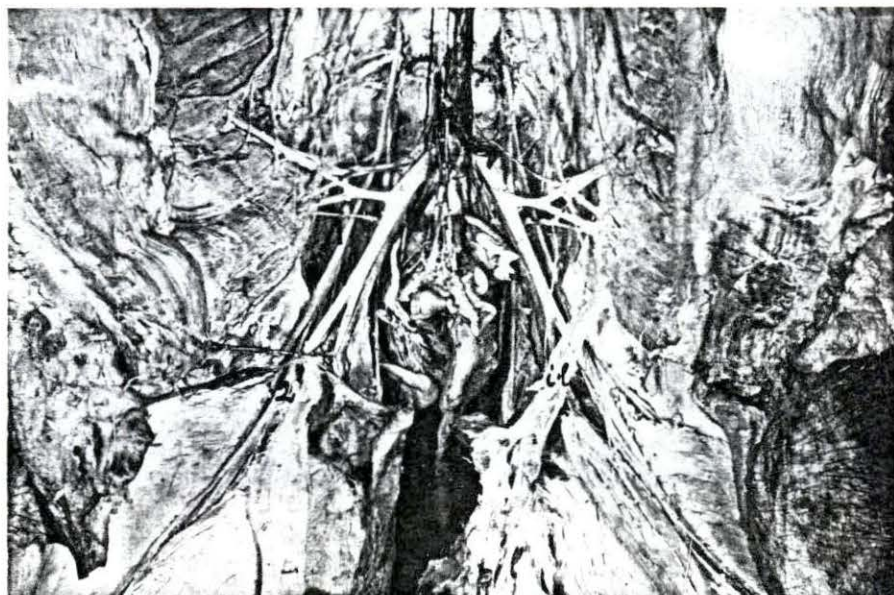


Plate 15. Origin of N. femoralis (1) and branching off of N. saphenus (2). Note the inguinal ligament (i.1) ventral view specimen no. 15 ♀.